

EAU Guidelines on **Penile Cancer**

O.W. Hakenberg (Chair), E. Comp erat, S. Minhas,
A. Necchi, C. Protzel, N. Watkin

TABLE OF CONTENTS

PAGE

1.	INTRODUCTION	4
	1.1 Aim and objectives	4
	1.2 Panel composition	4
	1.3 Available publications	4
	1.4 Publication history	4
2.	METHODS	4
	2.1 Data identification	4
	2.2 Review	4
	2.3 Future Goals	4
3.	EPIDEMIOLOGY, AETIOLOGY AND PATHOLOGY	5
	3.1 Definition of penile cancer	5
	3.2 Epidemiology	5
	3.3 Risk factors and prevention	6
	3.4 Pathology	7
	3.4.1 Gross handling	8
	3.4.2 Pathology report	8
	3.4.3 Grading	8
	3.4.4 Pathological prognostic factors	8
	3.4.5 Penile cancer and HPV	9
	3.4.6 Molecular biology	9
	3.4.7 Penile biopsy	9
	3.4.8 Intra-operative frozen sections and surgical margins	9
4.	STAGING AND CLASSIFICATION SYSTEMS	10
	4.1 TNM classification	10
5.	DIAGNOSTIC EVALUATION AND STAGING	11
	5.1 Primary lesion	11
	5.2 Regional lymph nodes	11
	5.2.1 Non-palpable inguinal nodes	11
	5.2.2 Palpable inguinal nodes	11
	5.3 Distant metastases	11
	5.4 Summary of evidence and recommendations for the diagnosis and staging of penile cancer	11
	5.4.1 Summary of Evidence for Diagnosis	11
	5.4.2 Recommendations for the diagnosis and staging of penile cancer	12
6.	DISEASE MANAGEMENT	12
	6.1 Treatment of the primary tumour	12
	6.1.1 Treatment of superficial non-invasive disease (CIS)	12
	6.1.2 Treatment of invasive disease confined to the glans (category Ta/T1a)	12
	6.1.3 Results of different surgical organ-preserving treatments	13
	6.1.3.1 Laser therapy	13
	6.1.3.2 Moh's micrographic surgery	13
	6.1.3.3 Glans resurfacing	13
	6.1.3.4 Glansectomy	14
	6.1.3.5 Partial penectomy	14
	6.1.3.6 Summary of results of surgical techniques	14
	6.1.4 Results of radiotherapy for T1 and T2 disease	14
	6.1.5 Summary of treatment recommendations for non-invasive and localised superficially invasive penile cancer	15
	6.1.5.1 Treatment of invasive disease confined to the corpus spongiosum/glans (T2)	15
	6.1.5.2 Treatment of disease invading the corpora cavernosa and/or urethra (T2/T3)	15

	6.1.5.3	Treatment of locally advanced disease invading adjacent structures (T3/T4)	15
	6.1.5.4	Local recurrence after organ-conserving surgery	15
	6.1.6	Guidelines for stage-dependent local treatment of penile carcinoma	15
6.2		Management of regional lymph nodes	16
	6.2.1	Management of patients with clinically normal inguinal lymph nodes (cN0)	16
	6.2.1.1	Surveillance	16
	6.2.1.2	Invasive nodal staging	16
	6.2.2	Management of patients with palpable inguinal nodes (cN1/cN2)	17
	6.2.2.1	Radical inguinal lymphadenectomy	17
	6.2.2.2	Pelvic lymphadenectomy	17
	6.2.2.3	Adjuvant treatment	18
	6.2.3	Management of patients with fixed inguinal nodes (cN3)	18
	6.2.4	Management of lymph node recurrence	18
	6.2.5	The role of radiotherapy for the treatment of lymph node disease	18
	6.2.6	Guidelines for treatment strategies for nodal metastases	19
6.3		Chemotherapy	19
	6.3.1	Adjuvant chemotherapy in node-positive patients after radical inguinal lymphadenectomy	19
	6.3.2	Neoadjuvant chemotherapy in patients with fixed or relapsed inguinal nodes	19
	6.3.3	Palliative chemotherapy in advanced and relapsed disease	20
	6.3.4	Intra-arterial chemotherapy	20
	6.3.5	Targeted therapy	20
	6.3.6	Guidelines for chemotherapy in penile cancer patients	20
7.		FOLLOW-UP	21
	7.1	Rationale for follow-up	21
	7.1.1	When and how to follow-up	21
	7.1.2	Recurrence of the primary tumour	21
	7.1.3	Regional recurrence	21
	7.1.4	Guidelines for follow-up in penile cancer	22
	7.2	Quality of life	22
	7.2.1	Consequences after penile cancer treatment	22
	7.2.2	Sexual activity and quality of life after laser treatment	22
	7.2.3	Sexual activity after glans resurfacing	22
	7.2.4	Sexual activity after glansectomy	22
	7.2.5	Sexual function after partial penectomy	23
	7.2.6	Quality of life after partial penectomy	23
	7.3	Total phallic reconstruction	23
	7.4	Specialised care	23
8.		REFERENCES	23
9.		CONFLICT OF INTEREST	33

1. INTRODUCTION

1.1 Aim and objectives

The European Association of Urology (EAU) Guidelines on Penile Cancer provides up-to-date information on the diagnosis and management of penile squamous cell carcinoma (SCC).

It must be emphasised that clinical guidelines present the best evidence available to the experts but following guideline recommendations will not necessarily result in the best outcome. Guidelines can never replace clinical expertise when making treatment decisions for individual patients, but rather help to focus decisions - also taking personal values and preferences/individual circumstances of patients into account.

1.2 Panel composition

The EAU Penile Cancer Guidelines Panel consists of an international multi-disciplinary group of clinicians, including a pathologist and an oncologist. Members of this panel have been selected based on their expertise and to represent the professionals treating patients suspected of having penile cancer. All experts involved in the production of this document have submitted potential conflict of interest statements, which can be viewed on the EAU website Uroweb: <http://uroweb.org/guideline/penile-cancer/>.

1.3 Available publications

A quick reference document (Pocket guidelines) is available, both in print and in a number of versions for mobile devices. These are abridged versions which may require consultation together with the full text version. Several scientific publications are available (the most recent paper dating back to 2014 [1]), as are a number of translations of all versions of the Penile Cancer Guidelines. All documents are available through the EAU website Uroweb: <http://uroweb.org/guideline/penile-cancer/>.

1.4 Publication history

The EAU Penile Cancer Guidelines were first published in 2000 with the most recent full update occurring in 2014.

2. METHODS

2.1 Data identification

A systematic literature search on penile cancer was performed between August 2008 and November 2013. All articles relating to penile cancer (n = 1,602) in the relevant literature databases were reviewed and 352 papers were considered suitable for adding to the research base of the Guidelines. Fully revised Guidelines were produced using the updated research base, together with several national and international guidelines on penile cancer (National Comprehensive Cancer Network [2], French Association of Urology [3] and the European Society of Medical Oncology [4]).

Recommendations in this text are assessed according to their level of evidence (LE) and Guidelines are given a grade of recommendation (GR), according to a classification system modified from the Oxford Centre for Evidence-Based Medicine Levels of Evidence [5]. Additional information can be found in the general Methodology section of this print, and online at the EAU website: <http://uroweb.org/guideline/>. A list of Associations endorsing the EAU Guidelines can also be viewed online at the above address.

2.2 Review

This document was subjected to independent peer review prior to publication in 2015.

2.3 Future Goals

The results of ongoing and new systematic reviews will be included in the 2017 update of the Penile Cancer Guidelines. These reviews are performed using standard Cochrane systematic review methodology; <http://www.cochranelibrary.com/about/about-cochrane-systematic-reviews.html>.

Ongoing systematic reviews:

1. What are the risks and benefits of primary radiation therapy vs. conservative surgery for penile cancer?
2. What are the risks and benefits of adjuvant radiotherapy after inguinal lymphadenectomy for penile cancer?

3. EPIDEMIOLOGY, AETIOLOGY AND PATHOLOGY

3.1 Definition of penile cancer

Penile carcinoma is usually a SCC, although there are other types of penile cancer (see Table 3). Penile SCC usually arises from the epithelium of the inner prepuce or the glans. Penile SCC exists in several histological subtypes. Its pathology is similar to SCC of the oropharynx, female genitalia (cervix, vagina and vulva) and anus and shares some of the natural history.

3.2 Epidemiology

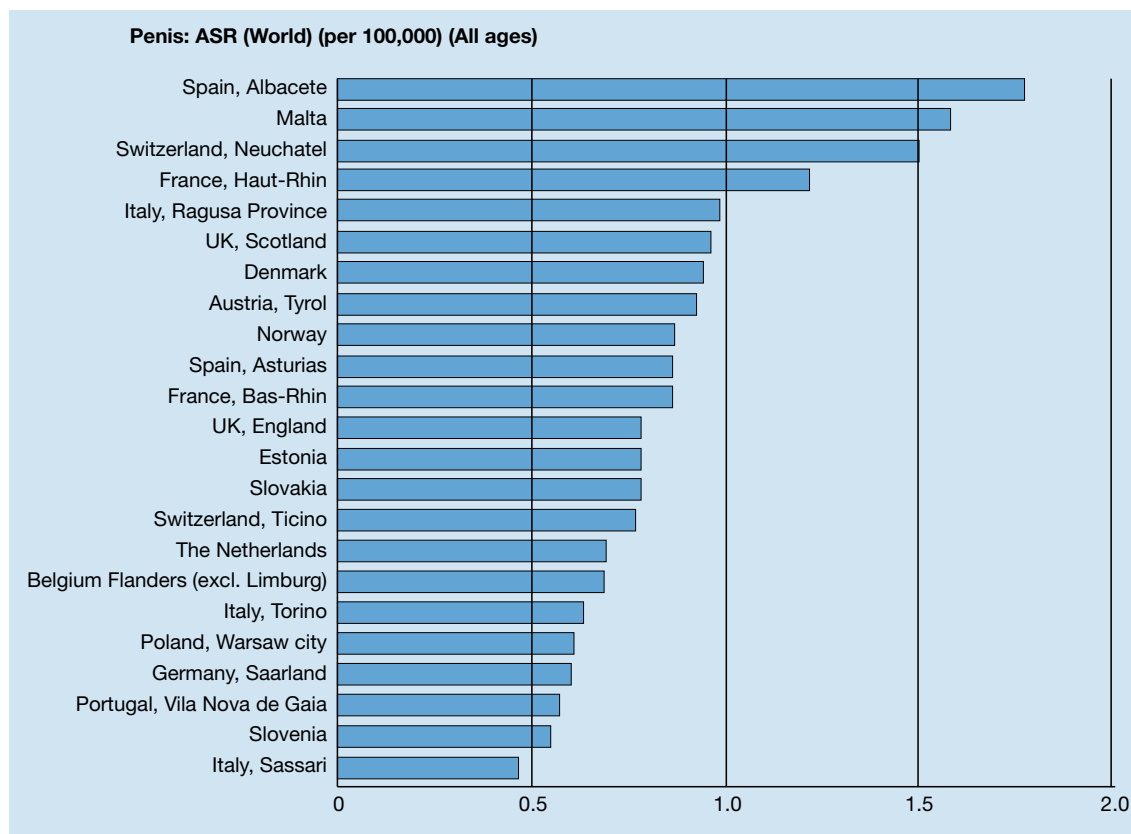
In the Western World, primary penile cancer is uncommon, with an overall incidence of < 1.00/100,000 males in Europe and the USA [6, 7], although there are several geographical areas in Europe with an incidence over 1.00/100,000 (Figure 1) [8]. In North America [6], the incidence of penile cancer is also affected by race and ethnicity, with the incidence highest in white Hispanics (1.01/100,000) compared to Alaskans, Native American Indians (0.77 /100,000), African Americans (0.62/100,000) and white non-Hispanics (0.51/100,000), respectively. In contrast, other parts of the world, such as South America, South East Asia and parts of Africa, have a much higher incidence, with penile cancer representing 1-2% [8] of malignant diseases in men.

Penile cancer is common in regions with a high prevalence of human papilloma virus (HPV) [6]. The annual age-adjusted incidence is 0.7-3.0/100,000 men in India, 8.3/100,000 men in Brazil and even higher in Uganda, where it is the most commonly diagnosed male cancer [8, 9]. The majority of knowledge about penile cancer comes from countries with a high incidence.

The incidence of penile cancer is related to the prevalence of HPV in the population, which may account for the variation in incidence, as the worldwide HPV prevalence varies considerably. There is also a less noticeable variation in incidence between European regions (Figure 1). At least one third of cases can be attributed to HPV-related carcinogenesis. There is no data linking penile cancer to human immunodeficiency virus (HIV) or acquired immune deficiency syndrome (AIDS).

In the USA, the overall age-adjusted incidence rate decreased from 1973 to 2002 from 0.84/100,000 in 1973-1982 to 0.69/100,000 in 1983-1992, and to 0.58/100,000 in 1993-2002 [6]. In Europe, the overall incidence has been stable from the 1980s until now [7], with an increased incidence reported in Denmark [10] and the UK. A UK longitudinal study confirmed a 21% increase in incidence from 1979-2009 [11]. The incidence of penile cancer increases with age [7]. The peak age is during the sixth decade of life, though the disease does occur in younger men [12].

Figure 1: Annual incidence rate (world standardised) by European region/country*



*Adapted from [8].

3.3 Risk factors and prevention

Review of the published literature from 1966-2000 identified several risk factors for penile cancer [13] (Table 1) (LE: 2a).

Table 1: Recognised aetiological and epidemiological risk factors for penile cancer

Risk factors	Relevance	Ref
Phimosis	OR 11-16 vs. no phimosis	[14, 15]
Chronic penile inflammation (balanoposthitis related to phimosis) Balanitis xerotica obliterans (lichen sclerosus)	Risk	[16]
Sporalene and UVA phototherapy for various dermatological conditions such as psoriasis	Incidence rate ratio 9.51 with > 250 treatments	[17]
Smoking	5-fold increased risk (95% CI: 2.0-10.1) vs. non-smokers	[14, 15, 18]
HPV infection condylomata acuminata	22.4% in verrucous SCC 36-66.3% in basaloid-warty	[6, 19]
Rural areas, low socioeconomic status, unmarried		[20-23]
Multiple sexual partners, early age of first intercourse	3-5-fold increased risk of penile cancer	[13, 15, 24]

HPV = human papilloma virus; OR = odds ratio; SCC = squamous cell carcinoma; UVA = ultraviolet A.

Human papilloma virus infection (HPV) is an important risk factor; HPV DNA was found in 70-100% of intraepithelial neoplasia and in 30-40% of invasive penile cancer tissue samples (LE: 2a). It is thought to be a cofactor in the carcinogenesis of some variants of penile SCC [19] through interaction with oncogenes and tumour suppressor genes (P53, Rb genes) [25]. The commonest HPV subtypes in penile cancer are types 16 and 18 [26] and the risk of penile cancer is increased in patients with condyloma acuminata [27] (LE: 2b).

It remains unclear whether HPV-associated penile cancer has a different prognosis to

non-HPV-associated penile cancer. A significantly better 5-year disease-specific survival was reported for HPV-positive vs. HPV-negative cases (93% vs. 78%) [28], while others reported no difference in lymph node metastases and 10-year survival rates [29].

There is no direct association between the incidence of penile cancer and cervical cancer. However, both cancers are independently linked with the prevalence of HPV infections [30, 31]. Female sexual partners of patients with penile cancer do not have an increased incidence of cervical cancer. There is no current recommendation for HPV vaccination in males because of the different HPV-associated risk pattern in penile and cervical cancer. The epidemiological effects of HPV vaccination in girls are also awaited [32, 33].

Phimosis is strongly associated with invasive penile cancer [15, 20, 34, 35], probably due to associated chronic infection since smegma is not a carcinogen [34]. A further risk factor suggested by epidemiological studies is cigarette smoking (4.5-fold increased risk (95% CI: 2.0-10.1) [35]. The incidence of lichen sclerosus (balanitis xerotica obliterans) in patients with penile cancer is relatively high but is not associated with increased rates of adverse histopathological features, including carcinoma in situ (CIS). Other epidemiological risk factors are low levels of socioeconomic status and education [20].

Countries and cultures practising routine neonatal circumcision have a lower incidence of penile cancer. Israeli Jews have the lowest incidence at 0.3/100,000/year. Neonatal circumcision removes approximately half the tissue that can develop into penile cancer. A USA study of a 100 matched case-control pairs found that the protective effect of neonatal circumcision against invasive penile cancer (OR 0.41) became much weaker when the comparative analysis was only against men without a history of phimosis (OR 0.79, 95% CI: 0.29-2 [15]). Neonatal circumcision does not reduce the risk of CIS [15].

3.4 Pathology

Squamous cell carcinoma accounts for > 95% of cases of penile malignancies (Tables 2 and 3). It is not known how often SCC is preceded by premalignant lesions (Table 3) [36-39]. Some variants of primary penile cancer have not yet been included in the World Health Organisation (WHO) classification, including pseudohyperplastic carcinoma, carcinoma cuniculatum, pseudoglandular carcinoma, and warty-basaloid carcinoma.

There are many mixed forms of SCC, including the warty-basaloid form (50-60% of mixed penile SCC), usual- verrucous (hybrid), usual-warty, usual-basaloid or usual-papillary and other rarer combinations.

Other penile malignant lesions include melanocytic lesions, mesenchymal tumours, lymphomas and metastases, these are unrelated to penile cancer and rarer. Aggressive penile sarcoma has been reported. Penile metastases from other neoplasias often have a prostatic or colorectal origin.

Table 2: Premalignant penile lesions (precursor lesions)

Lesions sporadically associated with SCC of the penis
<ul style="list-style-type: none"> • Cutaneous horn of the penis • Bowenoid papulosis of the penis • Lichen sclerosus (balanitis xerotica obliterans)
Premalignant lesions (up to one-third transform to invasive SCC)
<ul style="list-style-type: none"> • Intraepithelial neoplasia grade III • Giant condylomata (Buschke-Löwenstein) • Erythroplasia of Queyrat • Bowen's disease • Paget's disease (intra-dermal ADK)

Table 3: Histological subtypes of penile carcinomas, their frequency and outcome

Subtype	Frequency (% of cases)	Prognosis
Common SCC	48-65	Depends on location, stage and grade
Basaloid carcinoma	4-10	Poor prognosis, frequently early inguinal nodal metastasis [40]
Warty carcinoma	7-10	Good prognosis, metastasis rare
Verrucous carcinoma	3-8	Good prognosis, no metastasis
Papillary carcinoma	5-15	Good prognosis, metastasis rare
Sarcomatoid carcinoma	1-3	Very poor prognosis, early vascular metastasis
Mixed carcinoma	9-10	Heterogeneous group
Pseudohyperplastic carcinoma	< 1	Foreskin, related to lichen sclerosus, good prognosis, metastasis not reported
Carcinoma cuniculatum	< 1	Variant of verrucous carcinoma, good prognosis, metastasis not reported
Pseudoglandular carcinoma	< 1	High-grade carcinoma, early metastasis, poor prognosis
Warty-basaloid carcinoma	9-14	Poor prognosis, high metastatic potential [41] (higher than in warty, lower than in basaloid SCC)
Adenosquamous carcinoma	< 1	Central and peri-meatal glans, high-grade carcinoma, high metastatic potential but low mortality
Mucoepidermoid carcinoma	< 1	Highly aggressive, poor prognosis
Clear cell variant of penile carcinoma	1-2	Exceedingly rare, associated with HPV, aggressive, early metastasis, poor prognosis, outcome is lesion-dependent, frequent lymphatic metastasis [42]

3.4.1 **Gross handling**

Tissue sections must include entire small lesions and at least 3-4 blocks of larger lesions. Lymph nodes must be included in their entirety to ensure the detection of micrometastases. Surgical margins must also be completely included.

3.4.2 **Pathology report**

The pathology report must include the anatomical site of the primary tumour, the histological type/subtypes, grade, perineural invasion, depth of invasion, vascular invasion (venous/lymphatic), irregular growth and front of invasion, urethral invasion, invasion of corpus spongiosum/cavernosum and surgical margins.

3.4.3 **Grading**

The Tumour, Node, Metastasis (TNM) classification for penile cancer includes tumour grade because of its prognostic relevance (Table 4). Both Broder's classification and the WHO grading system for grading penile cancer are highly dependent on the observer and are no longer used [43].

3.4.4 **Pathological prognostic factors**

Carcinomas limited to the foreskin have a better prognosis and lower risk of regional metastasis [44]. Perineural invasion and histological grade are very strong predictors of poor prognosis and cancer-specific mortality [45]. Although, tumour grade is a predictor of metastatic spread it can be difficult to grade heterogeneous tumours. Lymphatic invasion is an independent predictor of metastasis. Venous embolism is often seen in advanced stages.

Types of penile SCC with an excellent prognosis include: verrucous, papillary, warty, pseudohyperplastic and carcinoma cuniculatum. These SCCs are locally destructive, rarely metastasise and have a very low cancer-related mortality.

High-risk SCC variants are the basaloid, sarcomatoid, adenosquamous and poorly differentiated types. They metastasise early and mortality rates are high. The intermediate-risk SCC group comprises the most common SCC, mixed forms and the pleomorphic form of warty carcinomas.

Stage pT3 tumours that invade the distal (glandular) urethra (25% of cases) do not have a worse outcome [46]. However, invasion of the more proximal urethra, also classified as stage pT3, is due to a highly aggressive SCC with a poor prognosis (see Table 3). The inclusion in the one pT2 group of cancers which invade the corpus spongiosum and the corpora cavernosa is confusing clinically as these conditions have very different prognoses. After a mean follow-up of 3 years, higher rates of local recurrence (35% vs. 17%) and mortality (30% vs. 21%) were reported in pT2 tumours (n = 72) with tunica or cavernosal involvement vs.

glans-only invasion, respectively [47] (LE: 2b). The Panel proposed defining T2a with spongiosum-only invasion and T2b with tunica and/or corpus cavernosum invasion. A similar prognostic difference was observed in a retrospective analysis of 513 patients treated between 1956 and 2006 [48].

Long-term survival is similar in patients with T2 and T3 tumours and in patients with N1 and N2 disease, using the 1987-2002 TNM classification [48] (LE: 2a).

Two nomograms, based only on small numbers, were developed to estimate prognosis in penile cancer. One study suggested that pT1G1 tumours are low-risk tumours, with 0% developing lymph node metastases, in contrast to high-risk pT2/3 G2/3 tumours, with 83% developing lymph node metastases [49].

Remaining tumours were intermediate-risk tumours with 33% developing metastases. Another study reported similar findings and recommended prophylactic lymphadenectomy for high-risk patients [50]. There is also a 'prognostic index', which ranks several pathological parameters (grade, deepest anatomical level, perineural invasion) to predict the likelihood of inguinal lymph node metastases and 5-year survival [51]. The lower the score, the higher the probability of 95% survival at 5 years.

3.4.5 **Penile cancer and HPV**

A high prevalence of HPV infection is found in basaloid (76%), mixed warty-basaloid (82%) and warty penile (39%) SCCs. The commonest HPV-types in penile SCC are HPV 16 (72%), HPV 6 (9%) and HPV 18 (6%). Verrucous and papillary penile SCCs are HPV-negative. Overall, only one-third of penile SCCs show HPV infection, but those that do are usually infected by several HPV strains.

3.4.6 **Molecular biology**

Little is known about the role of chromosomal abnormalities in penile SCC in relation to biological behaviour and patient outcome [25]. Lower DNA copy and alteration numbers are linked to poorer survival. Alterations in the locus 8q24 may play a major role and are implicated in other neoplasms such as prostate cancer [52, 53]. Telomerase activity has been shown in invasive penile carcinoma [54], and some authors have shown that aneuploidy changed according to tumour grade [55].

Epigenetic alterations evaluating the methylation pattern of CpG islands in CDKN2A have been described. CDKN2A encodes for two tumour suppressor proteins (p16INK4A and p14ARF) which control cell growth through Rb and p53 pathways. Poetsch *et al.* showed that 62% of invasive SCC of the penis displayed allelic loss of p16 and 42% displayed promoter hypermethylation. Tumours immunohistochemically negative for p16 showed hypermethylation of and/or loss of heterozygosity (LOH) near the p16INK4A locus. In that study, p16 negativity was linked to lymph node metastasis, in another study to prognosis [56]. Allelic loss of the p53 gene is a frequent event in penile SCC (42%) [57] and p53 expression has been linked to poor prognosis [58]. Another element influencing lymph node metastasis is the metastasis suppressor protein KAI1/CD82; decreased expression of this protein favours lymph node metastasis [59].

3.4.7 **Penile biopsy**

The diagnosis of penile cancer must be confirmed by biopsy. Although penile cancer is usually obvious, very occasionally it may be confused with non-SCC penile carcinoma or inflammatory lesions. Histological confirmation is necessary to guide management when:

- there is doubt about the exact nature of the lesion (e.g. CIS, metastasis or melanoma);
- treatment is planned with topical agents, radiotherapy or laser surgery;
- lymph node treatment is based on pre-operative histological information (risk-adapted strategy).

Biopsy size is important, in biopsies with an average size of 0.1 cm, it is difficult to evaluate the depth of invasion in 91% of biopsies. The grade at biopsy and in the final specimen may differ in up to 30% of cases with failure to detect cancer in 3.5% of cases [36]. Furthermore, vascular and lymphatic tumour emboli were detected in only 9-11% of cases. Although a punch biopsy may be sufficient for superficial lesions, an excisional biopsy is preferred as it should be deep enough to assess properly the degree of invasion and stage.

3.4.8 **Intra-operative frozen sections and surgical margins**

The aim of surgical treatment is complete removal of the penile carcinoma and negative surgical margins. The width of negative surgical margins should follow a risk-adapted strategy based on tumour grade. Negative surgical margins may be confirmed intra-operatively by frozen section [60]. If surgical margins are studied following these criteria (including urethral and periurethral tissue), only 5 mm of tumour-free tissue is sufficient to consider the surgical margins to be negative [61].

4. STAGING AND CLASSIFICATION SYSTEMS

4.1 TNM classification

The 2009 TNM classification [62] stratifies the T1 category into two prognostically different risk groups, depending on the presence or absence of lymphovascular invasion and grading (Table 4). The rationale for a potential further subdivision of the T2 category is discussed under Section 3.4.4 [47, 48].

The 2009 TNM classification recognizes the adverse effect of extracapsular spread on prognosis and therefore classifies any inguinal lymph node metastasis with extracapsular extension as pN3 [62]. Retroperitoneal lymph node metastases are extra-regional nodal and therefore distant metastases.

Table 4: 2009 TNM clinical and pathological classification of penile cancer [62]

Clinical classification	
T - Primary Tumour	
TX	Primary tumour cannot be assessed
T0	No evidence of primary tumour
Tis	Carcinoma in situ
Ta	Non-invasive carcinoma
T1	Tumour invades subepithelial connective tissue
T1a	Tumour invades subepithelial connective tissue without lymphovascular invasion and is not poorly differentiated or undifferentiated (T1G1-2)
T1b	Tumour invades subepithelial connective tissue with lymphovascular invasion or is poorly differentiated or undifferentiated (T1G3-4)
T2	Tumour invades corpus spongiosum and/or corpora cavernosa
T3	Tumour invades urethra
T4	Tumour invades other adjacent structures
N - Regional Lymph Nodes	
NX	Regional lymph nodes cannot be assessed
N0	No palpable or visibly enlarged inguinal lymph node
N1	Palpable mobile unilateral inguinal lymph node
N2	Palpable mobile multiple unilateral or bilateral inguinal lymph nodes
N3	Fixed inguinal nodal mass or pelvic lymphadenopathy, unilateral or bilateral
M - Distant Metastasis	
M0	No distant metastasis
M1	Distant metastasis
Pathological classification	
The pT categories correspond to the clinical T categories. The pN categories are based upon biopsy or surgical excision	
pN - Regional Lymph Nodes	
pNX	Regional lymph nodes cannot be assessed
pN0	No regional lymph node metastasis
pN1	Intranodal metastasis in a single inguinal lymph node
pN2	Metastasis in multiple or bilateral inguinal lymph nodes
pN3	Metastasis in pelvic lymph node(s), unilateral or bilateral or extranodal extension of any regional lymph node metastasis
pM - Distant Metastasis	
pM0	No distant metastasis
pM1	Distant metastasis
G - Histopathological Grading	
GX	Grade of differentiation cannot be assessed
G1	Well differentiated
G2	Moderately differentiated
G3-4	Poorly differentiated/undifferentiated

5. DIAGNOSTIC EVALUATION AND STAGING

Penile cancer can be cured in over 80% of cases if diagnosed early. Local treatment, although potentially lifesaving, can be mutilating and devastating for the patient's psychological well-being.

5.1 Primary lesion

Penile carcinoma is usually a clinically obvious lesion however, it may be hidden under a phimosis. Physical examination should include palpation of the penis to assess the extent of local invasion. Ultrasound (US) can give information about infiltration of the corpora [63, 64]. Magnetic resonance imaging (MRI) with an artificially induced erection can help to exclude tumour invasion of the corpora cavernosa if preservation of the penis is planned [65, 66].

5.2 Regional lymph nodes

Careful palpation of both groins for enlarged inguinal lymph nodes must be part of the initial physical examination of patients with penile cancer.

5.2.1 *Non-palpable inguinal nodes*

If there are no palpable lymph nodes, the likelihood of micrometastatic disease is about 25%. Imaging studies are not helpful in staging clinically normal inguinal regions, though imaging may be helpful in obese patients in whom palpation is unreliable or impossible:

- Inguinal US (7.5 MHz) can reveal abnormal nodes with some enlargement. The longitudinal/transverse diameter ratio and absence of the lymph node hilum are findings with relatively high specificity [67].
- Conventional computed tomography (CT) or MRI scans cannot detect micrometastases reliably [68].
- Imaging with ¹⁸FDG-positron emission tomography (PET)/CT does not detect lymph node metastases < 10 mm [69, 70].

The further diagnostic management of patients with normal inguinal nodes should be guided by pathological risk factors. Lymphovascular invasion, local stage and grade are risk factors for the likelihood of lymphatic metastasis [71, 72]. Nomograms are not accurate enough. Invasive lymph node staging is required in patients at intermediate- or high-risk of lymphatic spread (see Section 6.2).

5.2.2 *Palpable inguinal nodes*

Palpable lymph nodes are highly indicative of lymph node metastases. Physical examination should note the number of palpable nodes on each side and whether these are fixed or mobile. Additional inguinal imaging does not alter management (see Section 6) and is usually not required.

A pelvic CT scan can be used to assess the pelvic lymph nodes. Imaging with ¹⁸FDG-PET/CT has shown a high sensitivity of 88-100%, with a specificity of 98-100%, for confirming metastatic nodes in patients with palpable inguinal lymph nodes [70, 73].

5.3 Distant metastases

An assessment of distant metastases should be performed in patients with positive inguinal nodes [74-76] (LE: 2b). CT of the abdomen and pelvis and a chest X-ray are recommended. Thoracic CT is more sensitive than chest X-ray. PET/CT is an option for identifying pelvic nodal and distant metastases in patients with positive inguinal nodes [77].

There is no established tumour marker for penile cancer. The SCC antigen (SCC Ag) is increased in < 25% of penile cancer patients. One study found that SCC Ag did not predict occult metastatic disease, but was an indicator of disease-free survival in lymph-node-positive patients [78].

5.4 Summary of evidence and recommendations for the diagnosis and staging of penile cancer

5.4.1 *Summary of evidence for diagnosis*

Examination should include morphology, extent and invasion of penile structures.
Both groins should be examined and the number, laterality and characteristics of nodes recorded.
CT of chest, abdomen and pelvis is recommended for patients with inguinal lymph node metastasis.
MRI with artificial erection improves local staging for men being considered for organ preserving surgery.

5.4.2 Recommendations for the diagnosis and staging of penile cancer

Recommendations	GR
Primary tumour	
Perform a physical examination, record morphology, extent and invasion of penile structures.	C
Obtain MRI with artificial erection in cases for which organ-preserving surgery is intended.	
Inguinal lymph nodes	
For physical examination of both groins, record number, laterality and characteristics of inguinal nodes and: <ul style="list-style-type: none"> If nodes are not palpable, offer invasive lymph node staging in high-risk patients (see Section 6). If nodes are palpable, stage with a pelvic CT or PET/CT. 	C
Distant metastases	
In N+ patients, obtain an abdominopelvic CT scan and chest X-ray for systemic staging. Alternatively, stage with a PET/CT scan.	C
In patients with systemic disease or with relevant symptoms, obtain a bone scan.	

MRI = magnetic resonance imaging; CT = computed tomography; PET = positron emission tomography.

6. DISEASE MANAGEMENT

6.1 Treatment of the primary tumour

Treatment of the primary penile cancer lesion aims to remove the tumour completely, while preserving as much of the penis as possible without compromising radicality. Local recurrence has little effect on long-term survival so that organ preservation strategies can be used [79].

The overall quality of the available research evidence is low. There are no randomised controlled trials or observational studies for surgical management of localised penile cancer nor studies comparing surgical and non-surgical modalities.

Penile preservation appears to be superior in functional and cosmetic outcomes. It is the primary treatment method for men with localised penile cancer. However, there are no randomised studies comparing organ-preserving and ablative treatment strategies, only retrospective studies with a LE: 3 or less.

Histological diagnosis with local staging must be obtained in all cases, especially if considering non-surgical treatment modalities. Treatment of the primary tumour and of the regional nodes can be staged. It is mandatory to remove all malignant tissue with negative surgical margins. Patients must be counselled about all relevant treatment modalities.

Local treatment modalities for small and localised penile cancer include excisional surgery, external beam radiotherapy (EBRT), brachytherapy and laser ablation.

6.1.1 Treatment of superficial non-invasive disease (CIS)

For penile CIS, topical chemotherapy with imiquimod or 5-fluorouracil (5-FU) can be an effective first-line treatment. Both agents have relatively low toxicity and adverse events, but efficacy is limited. Complete responses have been reported in up to 57% of CIS cases [80]. Due to the high-rate of persistence and/or recurrence, close and long-term surveillance of such patients is required. If topical treatment fails, it should not be repeated.

Laser treatment can be used for CIS. Photodynamic control may be used in conjunction with carbon dioxide (CO₂) laser treatment [81].

Alternatively, total or partial glans resurfacing can be offered as a primary treatment modality for CIS and as a secondary treatment in case of treatment failure with topical chemotherapy or laser therapy. Glans resurfacing is a surgical technique which consists of complete abrasion of the glandular epithelium followed by covering with a split skin graft. With glans resurfacing for presumed non-invasive disease, up to 20% of patients are found to have superficial invasive disease [82].

6.1.2 Treatment of invasive disease confined to the glans (category Ta/T1a)

A penis-preserving strategy is recommended (GR: C) for small and localised invasive lesions (Ta/T1a). It is mandatory to do a biopsy to confirm diagnosis prior to using conservative treatments (GR: C). All patients must be circumcised before considering conservative non-surgical treatments. For tumours confined to the prepuce, radical circumcision alone may be curative provided that negative surgical margins are confirmed by definitive histology.

For all surgical treatment options, the intraoperative assessment of surgical margins by frozen section is recommended (GR: C) as tumour-positive margins lead to local recurrence [83]. Total removal of the glans (glansectomy) and prepuce has the lowest recurrence rate for the treatment of small penile lesions (2%) [83]. Negative surgical margins are imperative when using penile-conserving treatments (GR: C) and a margin of 5 mm is considered oncologically safe [83, 84].

Treatment choice depends on tumour size, histology, including stage and grade, localisation (especially relative to the meatus) and patient preference as there are no documented differences in long-term local recurrence rates between surgery, laser and radiation therapy.

6.1.3 **Results of different surgical organ-preserving treatments**

There are only retrospective case series for these treatments. The results have been reported heterogeneously therefore, the database for assessment is of limited quality.

6.1.3.1 *Laser therapy*

Laser ablation is carried out with a neodymium:yttrium-aluminum garnet (Nd:YAG) laser or a CO₂ laser [85-90]. Visualization may be improved by photodynamic diagnosis.

The results of CO₂ laser treatment have been reported by three studies all from the same institution [85-87]. Laser treatment was given in combination with radiotherapy or chemotherapy to patients with CIS or T1 penile cancers. Follow-up was 5 years (median) in all three studies. There is some overlap between the cohorts reported, with a total of 195 patients included in these retrospective series.

No cancer-specific deaths were reported. One study reported an estimated cumulative risk of local recurrence at 5 years of 10% with CIS (n = 106) and 16% with T1 (n = 78) tumours [85]. In all three series taken together, local recurrence ranged from 14% for CIS [87] to 23% for T1 tumours [86]. The reported rate of inguinal nodal recurrence after local CO₂ laser treatment was 0% [87] and 4% [86]. Secondary partial penectomy at 10 years was 3% and 10%, depending on the tumour (CIS vs. T1) and whether combination treatment had been given or not [85].

Four studies on the results of Nd:YAG laser treatment [88-91] reported on a total of 150 patients with a follow-up of at least 4 years. Local recurrence rates at last follow-up ranged across the four studies from 10% [88] to 48% [89]. In one study [90], recurrence-free survival rates were reported as 100%, 95% and 89% at 1, 2 and 5 years, respectively. Inguinal nodal recurrence was reported in 21% of patients [88]. Cancer-related deaths were reported in 2% [91] and 9% of patients [89], respectively. Three studies from the same institution, probably including overlapping patient cohorts, reported overall survival (OS) rates by censored or uncensored data which ranged from 100% at 4 years [88] and 95% [90] to 85% [92] at 7 years. The rate of secondary partial penectomy after initial Nd:YAG laser treatment was reported as 4% [90] and 45% [89], respectively. Complications, urinary and sexual function outcomes were assessed in only one study with 29 patients [88], none of which reported complications or a change in urinary and sexual function after successful Nd:YAG laser treatment.

Other studies have presented data on a variety of laser treatments with either a CO₂ laser, Nd:YAG laser, a combination of both, or a potassium titanyl phosphate (KTP) laser [93-96], with a mean follow-up of 32-60 months with stages CIS to T3 included. These studies reported on a total of 138 patients.

The cancer-specific survival (CSS) probability at 5 years was 95% in one study using the Kaplan-Meier method [94]. This was consistent with the finding from another study in which the cancer-specific mortality rate was relatively low at 2% at a mean follow-up of approximately 5 years [95]. Local recurrence rates were 11% [95], 19% [94] and 26% [96]. In one study recurrence-free survival at 5 years was estimated to be 88% [94].

6.1.3.2 *Moh's micrographic surgery*

Moh's micrographic surgery is a technique by which histological margins are taken in a geometrical fashion around a cone of excision. This technique has not been widely used. Only two studies reported a total of 66 patients [97, 98]. The original description [97] consisted of 33 consecutive patients treated between 1936 and 1986 and reported on 29 patients with at least 5 years follow-up. In each study there was one secondary penile amputation and one death from penile cancer. In Mohs series, 79% were cured at 5 years [97]. In the other series, 68% were recurrence-free after a median of 37 months and 8% had inguinal nodal recurrence and died of the disease [98]. The local recurrence rate was 32% in one series [98].

6.1.3.3 *Glans resurfacing*

Three studies have reported results with glans resurfacing [82, 99, 100] in a total of 71 patients with CIS or T1. The range of the median duration of follow-up in the three studies was 21-30 months. No cancer-specific deaths were reported, the rates of local recurrence were 0% [99] and 6% [100], without reports of nodal recurrence. There were no reported complications.

6.1.3.4 Glansectomy

Results of another fairly new technique, glansectomy, was reported in three studies [83, 101, 102], whilst a fourth study also reported on glans-preserving surgery [102]. A total of 68 patients with a follow-up of 114 months [101] and 63 months [102] were included. One patient (8%) had a local recurrence [101] and six patients (9%) had inguinal nodal metastases. No cancer-specific deaths were reported. Another group reported 87 patients with six local (6.9%), 11 regional (12.6%) and two systemic recurrences (2.3%), during a mean follow-up of 42 months [83].

6.1.3.5 Partial penectomy

Results of partial penectomy were reported in eight rather heterogeneous studies [87, 102-108] with 184 patients, with T1-T3 tumours, and follow-up from 40-194 months. Cancer specific mortality ranged from 0-27%, with local recurrence rates ranging from 4-50%. The 5-year OS rate was reported by three of the studies and ranged from 59-89% [105, 106, 108].

6.1.3.6 Summary of results of surgical techniques

There is not sufficient evidence to suggest a difference regarding the outcomes of different penis-sparing strategies, all generally appear to show good oncological outcomes. Although conservative surgery may improve quality of life (QoL), local recurrence is more likely than after radical surgery, e.g. partial penectomy (5-12% vs. 5%). In a large cohort of patients undergoing conservative surgery, isolated local recurrence was 8.9%, with a 5-year disease-specific survival rate of 91.7%. Tumour grade, stage and lymphovascular invasion appear to be predictors of local recurrence.

6.1.4 Results of radiotherapy for T1 and T2 disease

Radiation treatment of the primary tumour is an alternative organ-preserving approach with good results in selected patients with T1-2 lesions < 4 cm in diameter [109-114] (LE: 2b). External radiotherapy is given with a minimum dose of 60 Gy combined with a brachytherapy boost or brachytherapy on its own [110, 112]. Radiotherapy results are best with penile brachytherapy with local control rates ranging from 70-90% [110, 112]. The American Brachytherapy Society and the Groupe Européen de Curiethérapie-European Society of Therapeutic Radiation Oncology (ABS-GEC-ESTRO) consensus statement for penile brachytherapy reported good tumour control rates, acceptable morbidity and functional organ preservation for penile brachytherapy for T1 and T2 penile cancers [115]. The rates of local recurrence after radiotherapy are higher than after partial penectomy. With local failure after radiotherapy, salvage surgery can achieve local control [116]. Patients with lesions > 4 cm are not candidates for brachytherapy.

Common complications with radiotherapy include urethral stenosis (20-35%), glans necrosis (10-20%) and late fibrosis of the corpora cavernosa [117] (LE: 3). With brachytherapy, meatal stenosis occurs in > 40% of cases.

Table 6: Summary of reported complications and oncological outcomes of local treatments*

Treatment	Complications	Local recurrence	Nodal recurrence	Cancer-specific deaths	References
Nd:YAG laser	None reported	10-48%	21%	2-9%	[88-91]
CO ₂ -laser	Bleeding, meatal stenosis both < 1%	14-23%	2-4%	None reported	[85-87]
Lasers (unspecified)	Bleeding 8%, local infection 2%	11-26%	2%	2-3%	[93-96]
Moh's micrographic surgery	Local infection 3%, Meatal stenosis 6%	32%	8%	3-4%	[97, 98]
Glans resurfacing	None reported	4-6%	Not reported	Not reported	[82, 99, 100]
Glansectomy	None reported	8%	9%	None reported	[101, 102]
Partial penectomy	Not reported	4-13%	14-19%	11-27%	[87, 105, 106, 108]
Brachytherapy	Meatal stenosis > 40%	10-30%	Not reported	Not reported	[109, 110, 112]
Radiotherapy	Urethral stenosis 20-35%, Glans necrosis 10-20%	Not reported	Not reported	Not reported	[111, 114-117]

*The ranges are the lowest and highest number of occurrences reported in different series.

6.1.5 **Summary of treatment recommendations for non-invasive and localised superficially invasive penile cancer**

6.1.5.1 *Treatment of invasive disease confined to the corpus spongiosum/glans (T2)*

Total glansectomy, with or without resurfacing of the corporeal heads, is recommended [103] (LE: 3; GR: C). Radiotherapy is an option (see Section 6.1.6). Partial amputation should be considered in patients unfit for reconstructive surgery [116] (GR: C).

6.1.5.2 *Treatment of disease invading the corpora cavernosa and/or urethra (T2/T3)*

Partial amputation with a tumour-free margin with reconstruction is standard [113] (GR: C). A surgical margin of 5 mm is considered safe [83, 84]. Patients should remain under close follow-up. Radiotherapy is an option.

6.1.5.3 *Treatment of locally advanced disease invading adjacent structures (T3/T4)*

These are relatively rare (Europe 5%, Brazil 13%) [84]. Total penectomy with perineal urethrostomy is standard surgical treatment for T3 tumours [84] (GR: C).

In more advanced disease (T4), neoadjuvant chemotherapy may be advisable, followed by surgery in responders, as in the treatment of patients with fixed enlarged inguinal nodes (see Section 6.2.4) (GR: C). Otherwise, adjuvant chemotherapy or palliative radiotherapy are options (GR: C; see Sections 6.2.4 and 6.1.6).

6.1.5.4 *Local recurrence after organ-conserving surgery*

A second organ-conserving procedure can be performed if there is no corpus cavernosum invasion [61, 81, 84, 113] (GR: C). For large or high-stage recurrence, partial or total amputation is required [117] (GR: C). A total phallic reconstruction may be offered to patients undergoing total/subtotal amputation [118, 119].

6.1.6 **Guidelines for stage-dependent local treatment of penile carcinoma**

Primary tumour	Use organ-preserving treatment whenever possible	LE	GR
Tis	Topical treatment with 5-fluorouracil or imiquimod for superficial lesions with or without photodynamic control.	3	C
	Laser ablation with CO ₂ or Nd:YAG laser.		
	Glans resurfacing.		
Ta, T1a (G1, G2)	Wide local excision with circumcision CO ₂ or Nd:YAG laser surgery with circumcision.	3	C
	Laser ablation with CO ₂ or Nd:YAG laser.		
	Glans resurfacing.		
	Glansectomy with reconstructive surgery, with or without skin grafting.		
	Radiotherapy by external beam or as brachytherapy for lesions < 4 cm.		
T1b (G3) and T2 confined to the glans	Wide local excision plus reconstructive surgery, with or without skin grafting.	3	C
	Laser ablation with circumcision.		
	Glansectomy with circumcision and reconstruction.		
	Radiotherapy by external beam or brachytherapy for lesions < 4 cm in diameter.		
T2 with invasion of the corpora cavernosa	Partial amputation and reconstruction or radiotherapy by external beam or brachytherapy for lesions < 4 cm in diameter.	3	C
T3 with invasion of the urethra	Partial penectomy or total penectomy with perineal urethrostomy.	3	C
T4 with invasion of other adjacent structures	Neoadjuvant chemotherapy followed by surgery in responders. Alternative: palliative external beam radiation.	3	C
Local recurrence after conservative treatment	Salvage surgery with penis-sparing treatment in small recurrences or partial amputation.	3	C
	Large or high-stage recurrence: partial or total amputation.		

CO₂ = carbon dioxide; Nd:YAG = neodymium:yttrium-aluminium-garnet.

6.2 Management of regional lymph nodes

The development of lymphatic metastases in penile cancer follows the route of anatomical drainage. Inguinal and pelvic lymph nodes provide the regional drainage system for the penis, and the superficial and deep inguinal lymph nodes are the first regional nodal group to manifest lymphatic metastatic spread, which can be unilateral or bilateral [79].

All inguinal sentinel nodes appear to be located in the superior and central inguinal zones, with most in the medial superior zone [80]. No lymphatic drainage was observed from the penis to the two inferior regions of the groin and no direct drainage to the pelvic nodes was visualised. These findings confirm earlier studies [81, 82].

The second regional lymph node groups are the ipsilateral pelvic lymph nodes. Pelvic nodal disease does not seem to occur without ipsilateral inguinal lymph node metastasis and there are no reports of crossover metastatic spread from one inguinal side to the other pelvic side. Further metastatic lymph node spread from the pelvic nodes to para-aortic and paracaval nodes is outside the regional lymph node drainage system of the penis and is classified as systemic metastatic disease.

The management of regional lymph nodes is decisive for long-term patient survival. Cure can be achieved in metastatic disease confined to the regional lymph nodes. Lymphadenectomy is the treatment of choice for inguinal lymph node metastases (GR: B). Multimodal treatment combining surgery and polychemotherapy is often indicated.

Management of regional lymph nodes is stage-dependent. In clinically node-negative patients (cN0), micrometastatic disease occurs in about 25% of cases and is related to the local tumour stage and grade. In clinically positive lymph nodes (cN1/cN2), metastatic disease is highly likely and no time should be wasted on antibiotic treatment. Enlarged fixed inguinal lymph nodes (cN3) require multimodal treatment by chemotherapy and surgery. Even if present in only one node, capsular penetration and extranodal extension in lymph node metastasis carries a high-risk of progression and is classified as pN3, which also requires multimodal treatment.

6.2.1 Management of patients with clinically normal inguinal lymph nodes (cN0)

Risk stratification for the management of patients with clinically normal lymph nodes depends on stage, grade and the presence or absence of lymphovascular invasion in the primary tumour [83]. Tumours with low-risk of metastatic disease are those with superficial penile cancer (pTa, pTis) and low grade. pT1 tumours are a heterogeneous risk group: low-risk if they are well differentiated (pT1G1), intermediate-risk group (pT1G2) [84] or high-risk (pT1G3 and all higher stages).

Early inguinal lymphadenectomy in clinically node-negative patients is far superior for long-term patient survival compared to therapeutic lymphadenectomy when regional nodal recurrence occurs [85, 86]. One prospective study comparing bilateral lymphadenectomy, radiotherapy and surveillance in clinically node-negative patients reported that 5-year OS was significantly better with inguinal lymphadenectomy vs. immediate inguinal radiotherapy or that observed with a surveillance strategy (74% vs. 66% and 63%, respectively) [87].

6.2.1.1 Surveillance

The surveillance of regional lymph nodes carries the risk of regional recurrence arising later from existing micrometastatic disease. Patient survival is over 90% with early lymphadenectomy and below 40% with lymphadenectomy for later regional recurrence [88, 89]. This risk must be taken into account when considering surveillance and the patient informed. Surveillance can only be recommended in patients with pTis and pTa penile cancer and with the appropriate caveats in pT1G1 tumours [88-90]. A prerequisite for surveillance is good patient information and compliance.

6.2.1.2 Invasive nodal staging

Staging of the inguinal lymph nodes in cN0 penile cancer requires an invasive procedure since all imaging techniques (US, CT, MRI) are unreliable in excluding small and micrometastatic lymph node involvement. Although CT criteria other than size have been defined for retrospective detection of lymph node metastases, these have not been validated prospectively [91]. Nomograms are unreliable in predicting node involvement [88, 92, 93] (LE: 2b). Fine-needle aspiration cytology does not reliably exclude micrometastatic disease and is not recommended. Instead, pathological risk factors are used to stratify node-negative patients [86, 94] (LE: 2b).

There are two invasive diagnostic procedures, whose efficacy is evidence-based: modified inguinal lymphadenectomy (mILND) and dynamic sentinel-node biopsy (DSNB). Both are standard approaches for invasive diagnosis of inguinal lymph nodes in clinically node-negative patients.

Modified ILND is the standard surgical approach. Both the superficial inguinal lymph nodes from at least the central and both superior Daseler's zones are removed bilaterally [79, 95] (LE: 3), leaving behind the

greater saphenous vein.

Dynamic sentinel node biopsy (DSNB) is based on the assumption that primary lymphatic drainage from a penile cancer initially goes to one or only a few inguinal sentinel nodes on each side before further dissemination to more inguinal nodes. Technetium-99m (Tc99m) nanocolloid is injected around the penile cancer site on the day before surgery; patent blue can be injected as well before surgery. A gamma-ray detection probe is used intra-operatively to detect the sentinel node in 97% of cases. The protocol has been standardised for routine use and has a short learning curve [96] (GR: B). DSNB has a reported high sensitivity (90-94%) [96, 97] (LE: 2b). In a pooled meta-analysis of 18 studies, pooled sensitivity was 88%, which improved to 90% with the addition of patent blue [98].

Both methods of invasive regional lymph node staging in cN0 patients may miss micrometastatic disease leading to regional recurrence and greatly reduced long-term survival [85]. The false-negative rate may be as high as 12-15% for DSNB, even in experienced centres [89, 90]. The false-negative rate of mLND is unknown. The patient must be informed of the risk of a false-negative result and the method being used. If lymph node metastasis is found with either method, an ipsilateral radical inguinal lymphadenectomy is indicated.

6.2.2 **Management of patients with palpable inguinal nodes (cN1/cN2)**

With uni- or bilateral palpable inguinal lymph nodes (cN1/cN2), metastatic lymph node disease is very likely and the traditional clinical advice to prescribe antibiotic treatment to exclude lymph node enlargement due to infection is no longer correct. Instead, appropriate oncological diagnosis and treatment should be undertaken without delay before further metastatic spread occurs. In clinically doubtful cases, US-guided fine needle aspiration cytology is an option [120].

With palpably enlarged inguinal lymph nodes, additional staging using imaging is not useful, except in very obese patients. However, CT or MRI can provide information about the pelvic nodal status. ¹⁸F-FDGPET/CT can identify additional metastases in lymph-node positive patients [121]. Dynamic sentinel node biopsy (DSNB) is not reliable in patients with palpably enlarged and suspicious inguinal lymph nodes and should not be used [122] (LE: 3).

6.2.2.1 *Radical inguinal lymphadenectomy*

In clinically lymph node positive patients, surgical staging by inguinal lymphadenectomy is indicated. Intraoperative frozen sections may be used to confirm lymph node metastasis, for which an ipsilateral radical inguinal lymphadenectomy is necessary [79, 84].

Radical inguinal lymphadenectomy carries a significant morbidity due to impaired lymph drainage from the legs and often problematic wound healing. Morbidity can be as high as 50% [123] in the presence of significant risk factors such as increased body mass index. However, recent series have reported lower morbidities of about 25% [124, 125] (LE: 2b). Therapeutic radical inguinal lymphadenectomy can be life-saving and should not be underused for fear of associated morbidity [126]. Lymph node density is a prognostic factor [127].

Tissue handling must be meticulous and take into account the absence of smooth muscle in lymphatic vessel walls. Lymphatic vessels therefore cannot be electrocoagulated and must be closed by ligation or possibly liberal use of clips [128, 129]. Post-operative morbidity is reduced by additional measures to improve drainage, such as stockings, bandaging, inguinal pressure dressings or vacuum suction [130] and prophylactic antibiotics. Advanced cases may require reconstructive surgery for primary wound closure.

The most commonly reported complications in recent series were wound infections (1.2-1.4%), skin necrosis (0.6-4.7%), lymphoedema (5-13.9%) and lymphocele formation (2.1-4%) [124, 125].

Laparoscopic and robot-assisted inguinal lymphadenectomy is feasible, but may not provide any advantage [131-134].

6.2.2.2 *Pelvic lymphadenectomy*

Patients with positive pelvic nodes have a worse prognosis compared to patients with only inguinal nodal metastasis (5-year CSS 71.0% vs. 33.2%) [135]. In the same study with 142 node-positive patients, significant risk factors for pelvic nodal metastasis were the number of positive inguinal nodes (cut-off 3), the diameter of inguinal metastatic nodes (cut-off 30 mm) and extranodal extension. The percentage of pelvic nodal metastases was 0% without any of these risk factors and 57.1% with all three risk factors [135].

If two or more positive lymph nodes, or one node with extracapsular extension (pN3), are found unilaterally, an ipsilateral pelvic lymphadenectomy is indicated. There is no direct lymphatic drainage from penile tumours to the pelvic lymph nodes [136] and lymphadenectomy is therefore not indicated if there is no involvement of inguinal nodes on that side. This recommendation is based on a study in which the rate of positive pelvic nodes was found to be 23% in cases with more than two positive inguinal nodes and 56% in those with more than three positive inguinal nodes, or if there was extracapsular involvement in at least one

inguinal node [84, 137] (LE: 2b).

Pelvic lymphadenectomy may be performed simultaneously or as a secondary procedure following definitive histology. If bilateral pelvic dissection is indicated, it can be performed through a midline suprapubic extraperitoneal incision. It is important to avoid unnecessary delay if these procedures are indicated [138].

6.2.2.3 *Adjuvant treatment*

In patients with pN2/pN3 disease, adjuvant chemotherapy is recommended [139] (GR: C) (see Section 6.3.1). This is because a retrospective study reported long-term disease-free survival of 84% in node-positive patients with adjuvant chemotherapy after radical lymph node surgery vs. 39% in historical controls without chemotherapy after lymphadenectomy [139].

Although adjuvant radiotherapy has been used after inguinal lymphadenectomy, the data is very limited and it is not generally recommended (see Section 6.2.5). There are no data for neoadjuvant inguinal radiotherapy.

6.2.3 **Management of patients with fixed inguinal nodes (cN3)**

Metastatic disease is always present in these cases. Staging by thoracic, abdominal and pelvic CT scan is necessary to assess the presence of further pelvic nodal disease and systemic metastatic disease. In clinically unequivocal cases, histological verification by biopsy is not required. Rare cases with reasonable doubt require an excisional or core needle biopsy.

These patients have a poor prognosis and are unlikely to be cured by surgery alone. Upfront surgery is not generally recommended (GR: B) as it is non-curative and usually destructive. Multimodal treatment with neoadjuvant chemotherapy followed by radical lymphadenectomy in clinically responsive cases is recommended [140-142]. Responders to neoadjuvant chemotherapy with post-chemotherapy surgery have been reported to achieve long-term survival in 37% of cases [140]. There may be individual patients with reasons for upfront surgery followed by adjuvant treatment.

6.2.4 **Management of lymph node recurrence**

Patients with regional recurrence after surveillance should be treated similarly to patients with primary cN1/cN2 disease (see Section 6.2.2). Patients with regional recurrence following negative invasive staging by DSNB or modified inguinal lymphadenectomy already have disordered inguinal lymphatic drainage and are at a high-risk of irregular metastatic progression. Patients with inguinal nodal recurrence after therapeutic radical inguinal lymphadenectomy have a 5-year CSS rate of 16% [143].

There is no evidence for the best management in such cases. Multimodal treatment with neoadjuvant and/or adjuvant chemotherapy after radical lymph node surgery is advised.

6.2.5 **The role of radiotherapy for the treatment of lymph node disease**

The use of radiotherapy for nodal disease follows tradition and single-institution policies and is not evidence-based. Despite the lack of data, radiotherapy is widely used in some European countries to manage regional lymph node metastasis in penile cancer.

It has not been reported that neoadjuvant or adjuvant radiotherapy improves oncological outcome in node-positive penile cancer [144]. One prospective trial found that inguinal node dissection was superior to inguinal radiotherapy [145]. Another study reported poor long-term survival in patients with adjuvant inguinal and pelvic radiotherapy [146]. Adjuvant chemotherapy has been reported to be far superior to adjuvant radiotherapy after radical inguinal lymphadenectomy in node-positive patients in one retrospective series [139]. Using the National Cancer Institute Surveillance, Epidemiology and End Results (SEER) Program database, treatment results of 2,458 penile cancer patients treated with either surgery alone or surgery plus EBRT showed that the addition of adjuvant radiotherapy 'had neither a harmful nor a beneficial effect on CSS' [147].

Due to the lack of evidence, radiotherapy in the treatment of lymph node disease in penile cancer is not generally recommended. Prophylactic radiotherapy for cN0 disease is not indicated. Adjuvant inguinal radiotherapy may be considered as an option in selected patients with extracapsular nodal extension (cN3) or as a palliative treatment for surgically irresectable disease.

6.2.6 Guidelines for treatment strategies for nodal metastases

Regional lymph nodes	Management of regional lymph nodes is fundamental in the treatment of penile cancer	LE	GR
No palpable inguinal nodes (cN0)	Tis, Ta G1, T1G1: surveillance.	2a	B
	> T1G2: invasive lymph node staging by bilateral modified inguinal lymphadenectomy or DSNB.	2a	B
Palpable inguinal nodes (cN1/cN2)	Radical inguinal lymphadenectomy.		
Fixed inguinal lymph nodes (cN3)	Neoadjuvant chemotherapy followed by radical inguinal lymphadenectomy in responders.		
Pelvic lymphadenopathy	Ipsilateral pelvic lymphadenectomy if two or more inguinal nodes are involved on one side (pN2) and if extracapsular nodal metastasis (pN3) is confirmed.	2a	B
Adjuvant chemotherapy	In pN2/pN3 patients after radical lymphadenectomy.	2b	B
Radiotherapy	Do not use for the treatment of nodal disease in penile cancer.		

DSNB = dynamic sentinel node biopsy.

6.3 Chemotherapy

6.3.1 Adjuvant chemotherapy in node-positive patients after radical inguinal lymphadenectomy

Multimodal treatment can improve patient outcome in many tumour types. Adjuvant chemotherapy after resection of nodal metastases in penile carcinoma has been reported in a few small and heterogeneous series [140, 148-151]. Comparing different small-scale clinical studies is fraught with difficulty.

The value of adjuvant chemotherapy after radical inguinal lymphadenectomy in node-positive penile cancer was demonstrated by an Italian group who reported long-term disease-free survival (DFS) of 84% in 25 consecutive patients treated with 12 adjuvant weekly courses of vincristine, bleomycin, and methotrexate (VBM) during the period 1979-1990 and compared this to a historical control group of 38 consecutive node-positive patients with radical lymphadenectomy (with- or without adjuvant inguinal radiotherapy) who had achieved a DFS rate of only 39% [140].

This group has also published results of a chemotherapy regimen adjuvant to radical lymphadenectomy in stage pN2-3 patients receiving three courses of cisplatin and 5-FU which they had been using since 1991 with lower toxicity and even better results compared to VBM [150] (LE: 2b). The same group has been using an adjuvant taxane-based regimen since 2004, cisplatin, 5-fluorouracil (5-FU) plus paclitaxel or docetaxel (TPF), in 19 node-positive patients receiving 3-4 cycles of TPF after resection of pN2-3 disease [151]. Of those patients, 52.6% were disease-free after a median follow up of 42 months and tolerability was good. Results of adjuvant treatment with paclitaxel and cisplatin also improved outcome [152].

The use of adjuvant chemotherapy is recommended, in particular when the administration of the triple combination chemotherapy is feasible, and curative treatment is aimed for (LE: 2b). No data for the adjuvant chemotherapeutic treatment of penile carcinoma in stage pN1 are available. The administration of an adjuvant treatment in pN1 disease is therefore recommended only in clinical trials.

6.3.2 Neoadjuvant chemotherapy in patients with fixed or relapsed inguinal nodes

Bulky inguinal lymph node enlargement (cN3) indicates extensive lymphatic metastatic disease. Primary lymph node surgery is not generally recommended (GR: B). Complete surgical resection is unlikely and only a few patients will benefit from surgery alone.

Very limited data is available on neoadjuvant chemotherapy before inguinal lymph node surgery. This approach enables early treatment of likely systemic disease and down-staging of inguinal lymph node disease. Complete surgical treatment is possible with a good clinical response.

Results were modest in retrospective studies of 5-20 patients treated with bleomycin-vincristine-methotrexate (BVM) and bleomycin-methotrexate-cisplatin (BMP) treatments [141, 142, 153] and in the confirmatory BMP trial of the Southwest Oncology Group [154]. However, treatment-related toxicity was unacceptable due to bleomycin-related mortality.

Cisplatin/5-FU (PF) chemotherapy achieved a response rate of 25-50% with more acceptable tolerability [155, 156]. Over a period of 30 years, five different neoadjuvant chemotherapy regimens were used in 20 patients [79], with long-term survival in 37% of chemotherapy responders who underwent surgery. In the European Organisation for Research and Treatment of Cancer study 30992, 26 patients with locally advanced or metastatic disease received irinotecan and cisplatin chemotherapy. Although the study did not meet its primary endpoint (response rate), there were three cases of pathologically complete remissions (pCR) [157].

A phase II trial evaluated treatment with four cycles of neoadjuvant paclitaxel, cisplatin, and ifosfamide (TIP). An objective response was reported in 15/30 patients, including three pCRs, which was a marginally significant predictor of survival. The estimated median time to progression (TTP) was 8.1 months and the median OS rate was 17.1 months [158] (LE: 2a).

Similarities between penile SCC and head and neck SCC led to the evaluation in penile cancer of chemotherapy regimens with an efficacy in head and neck SCC, including taxanes. The combination of cisplatin and 5-FU plus a taxane has been used in a neoadjuvant and adjuvant setting [151]. An overall objective response rate of 44% was reported in 28 patients treated neoadjuvantly, including 14% pCR (LE: 2b).

Similarly, a Cancer Research UK phase II trial with TPF (using only docetaxel) reported an objective response of 38.5% in 29 locally advanced or metastatic patients, although the study did not meet its primary endpoint. However, there was significant toxicity [159] (LE: 2a).

Overall, these results support the use of neoadjuvant chemotherapy in patients with fixed, unresectable nodal disease, particularly with a triple combination, including cisplatin and a taxane, whenever feasible (LE: 2a; GR: B).

There are hardly any data concerning radiochemotherapy with lymph-node surgery in penile cancer. Radiochemotherapy should only be offered in clinical trials [160].

6.3.3 **Palliative chemotherapy in advanced and relapsed disease**

A recent retrospective study of individual patient data of 140 men with advanced penile SCC reported that visceral metastases and an ECOG-performance status > 1 were independent prognostic factors, and that cisplatin-based regimens had better outcomes than non-cisplatin-based regimens after adjusting for prognostic factors [161] (LE: 3).

In clinical practice however, first-line chemotherapy regimens are variable. Before taxanes were introduced, the data were limited by small numbers, patient heterogeneity and its retrospective nature (except for the EORTC trial [157]). Initial response rates ranged from 25% to 100%, with very few sustained responses and very few long-term survivors. The introduction of taxanes into penile cancer chemotherapy has enhanced the activity and efficacy of the regimens used [79, 141, 142, 152-159, 162].

There is virtually no data on second-line chemotherapy in penile cancer. One report using second-line paclitaxel monotherapy reported an initial response rate under 30%. Therefore, this may be a reasonable option however, no patients survived [163] (LE: 2a; GR: B). Anecdotally, a benefit has been observed by combining cisplatin with gemcitabine [164] (LE: 4).

6.3.4 **Intra-arterial chemotherapy**

Intra-arterial chemotherapy has been trialled in locally advanced cases, especially cisplatin and gemcitabine in small case series [165-168]. Apart from a limited clinical response, outcome was not significantly improved.

6.3.5 **Targeted therapy**

Targeted drugs have been used as second-line treatment and they could be considered as single-agent treatment in refractory cases. Anti-epidermal growth factor receptor (EGFR) targeted monotherapy has been trialled as EGFR is expressed in penile SCC [165, 166] and the assumed similarities with head and neck SCC [166, 167]. There have been other studies, particularly with the anti-EGFR monoclonal antibodies, panitumumab and cetuximab. Some activity of tyrosine kinase inhibitors has been reported as well [168]. Further clinical studies are needed (LE: 4).

6.3.6 **Guidelines for chemotherapy in penile cancer patients**

Recommendations	LE	GR
Treat with adjuvant chemotherapy (3-4 cycles of TPF) in patients with pN2-3 tumours.	2b	C
Treat with neoadjuvant chemotherapy (4 cycles of a cisplatin and taxane-based regimen) followed by radical surgery in patients with non-resectable or recurrent lymph node metastases.	2a	B
In patients with systemic disease and a limited metastatic load, treat with chemotherapy.	3	C

TPF = cisplatin, 5-fluorouracil, paclitaxel

7. FOLLOW-UP

7.1 Rationale for follow-up

The early detection of recurrence during follow-up increases the likelihood of curative treatment. Local recurrence does not significantly reduce long-term survival if successfully treated. In contrast, disease that has spread to the inguinal lymph nodes greatly reduces the rate of long-term disease-specific survival. Follow-up is also important in the detection and management of treatment-related complications.

Local or regional nodal recurrences usually occur within 2 years of primary treatment [79]. After 5 years, all recurrences were either local recurrences or new primary lesions [79]. These results support an intensive follow-up regimen during the first 2 years, with a less intensive follow-up after this for a total of at least 5 years. Follow-up after 5 years may be omitted in motivated patients reliably able to continue to carry out regular self-examination [79].

7.1.1 *When and how to follow-up*

In patients with negative inguinal nodes after local treatment, follow-up should include physical examination of the penis and the groins for local and/or regional recurrence. Additional imaging has no proven benefit.

Follow-up also depends on the primary treatment modality. Histology from the glans should be obtained to confirm disease-free status following laser ablation or topical chemotherapy.

After potentially curative treatment for inguinal nodal metastases, CT or MRI imaging for the detection of systemic disease should be performed at 3-monthly intervals for the first 2 years so patients can benefit from adjuvant chemotherapy.

Although rarely late local recurrences may still occur, life-threatening metastases become very unusual after 5 years. This means regular follow-up can be stopped after 5 years, provided the patient understands the need to report any local changes immediately [169]. In patients unlikely to self-examine, long-term follow-up may be necessary.

7.1.2 *Recurrence of the primary tumour*

Local recurrence is more likely with all types of local organ-preserving treatment, i.e. after local excision, laser treatment, brachytherapy and associated therapies. However, it is very unlikely to increase the risk of dying from the disease in contrast to regional recurrence [79, 170]. Local recurrence occurred during the first 2 years in up to 27% of patients treated with penis-preserving modalities [171]. After partial penectomy, the risk of local recurrence is about 4-5% [79, 170, 171].

Local recurrence is easily detected by physical examination by the patient himself or his physician. Patient education is an essential part of follow-up and the patient should be urged to visit a specialist if any changes are seen.

7.1.3 *Regional recurrence*

Most regional recurrences occur during the first 2 years after diagnosis and treatment, irrespective of whether a surveillance strategy has been used or a sentinel-node based management or modified inguinal lymphadenectomy.

Although very unlikely, regional recurrence can occur unexpectedly after 2 years. It is therefore wise to continue close follow-up in these patients, for whom self-examination is very important [172]. The highest rate of regional recurrence (9%) occurs in patients managed using a surveillance strategy, while the lowest is in patients who have undergone invasive nodal staging by modified inguinal lymphadenectomy or DSNB and whose lymph nodes were negative (2.3%).

The use of US and fine needle aspiration cytology (FNAC) in suspicious cases has improved the early detection rate of regional recurrence [67, 172, 173]. There are no data to support the routine use of CT or MRI for the follow-up of regional nodes.

Patients who have had surgical treatment for lymph node metastases without adjuvant treatment have an increased risk of regional recurrence of 19% [79]. Regional recurrence requires timely treatment by radical inguinal lymphadenectomy and adjuvant therapy (see Section 6).

7.1.4 Guidelines for follow-up in penile cancer

	Interval of follow-up		Examinations and investigations	Minimum duration of follow-up	GR
	Years 1-2	Years 3-5			
Recommendations for follow-up of the primary tumour					
Penile-preserving treatment	3 months	6 months	Regular physician or self-examination. Repeat biopsy after topical or laser treatment for CIS.	5 years	C
Amputation	3 months	1 year	Regular physician or self-examination.	5 years	C
Recommendations for follow-up of the inguinal lymph nodes					
Surveillance	3 months	6 months	Regular physician or self-examination.	5 years	C
pN0 at initial treatment	3 months	1 year	Regular physician or self-examination. Ultrasound with FNAB optional.	5 years	C
pN+ at initial treatment	3 months	6 months	Regular physician or self-examination. Ultrasound with FNAC optional, CT/MRI optional.	5 years	C

CIS = carcinoma in situ; CT = computed tomography; FNAB = fine-needle aspiration biopsy; FNAC = fine-needle aspiration cytology; MRI = magnetic resonance imaging.

7.2 Quality of life

7.2.1 Consequences after penile cancer treatment

In patients with long-term survival after penile cancer treatment, sexual dysfunction, voiding problems and cosmetic penile appearance may adversely affect the patient's QoL [174]. There is very little data on sexual function and QoL after treatment for penile cancer.

7.2.2 Sexual activity and quality of life after laser treatment

A retrospective interview-based Swedish study after laser treatment for penile CIS [93] in 58/67 surviving patients with a mean age of 63 years, of whom 46 participated, reported a marked decrease in some sexual practices, such as manual stimulation, caressing and fellatio, but a general satisfaction rate with life overall including their sex lives, similar to that of the general Swedish population.

A large study on CO₂ laser treatment of penile cancer in 224 patients reported no problems with erectile capability or sexual function following treatment [85]. In another study [96], no sexual dysfunction occurred in 19 patients treated.

7.2.3 Sexual activity after glans resurfacing

In one study with 10 patients [99], 7/10 completed questionnaires (International Index of Erectile Function [IIEF-5] and a non-validated 9-item questionnaire) at their 6-month follow-up visit. There was no erectile dysfunction according to the median IIEF-5 score of 24. All patients who were sexually active before treatment were active again within 3-5 months. According to the (non-validated) questionnaire, 7/7 patients stated that the sensation at the tip of their penis was either no different or better after surgery and that they had erections within 2-3 weeks of surgery. Six out of seven patients had had sexual intercourse within 3 months of surgery and 5/7 patients felt that their sex life had improved. Overall patient satisfaction with glans resurfacing was high.

7.2.4 Sexual activity after glansectomy

Two studies reported sexual function after glansectomy [101, 102]. In one study (n = 68) with unclear methodology [101], 79% did not report any decline in spontaneous erection, rigidity and penetrative capacity after surgery, while 75% reported recovery of orgasm. In another study [102], all 12 patients had returned to 'normal' sexual activity 1 month after surgery.

7.2.5 **Sexual function after partial penectomy**

Sexual function after partial penectomy was reported by three studies [175-177]. The IIEF questionnaire was used in 18 patients with a mean age of 52 years [175]. Post-operative scores were statistically worse for all domains of sexual function after partial penectomy. After surgery, 55.6% of patients had erectile function that allowed sexual intercourse. In patients who did not resume sexual intercourse after partial penectomy, 50% were ashamed of their small penis and missing glans, while another third blamed surgical complications. Of those who had resumed sexual intercourse, 66.7% reported the same frequency and level of sexual activity as before surgery, while 72.2% continued to have ejaculation and orgasm every time they had sexual activity. Overall, only 33.3% maintained their pre-operative frequency of sexual intercourse and were satisfied with their sex life.

An 'Overall Sexual Functioning Questionnaire' was used in 14/18 patients with a median time since surgery of 11.5 months (range 6-72) [176]. Prior to surgery, all patients had normal erectile function and intercourse at least once a month. In 9/14 patients, sexual functioning was 'normal' or 'slightly decreased', while 3/14 patients had no sexual intercourse after surgery. Alei *et al.* showed an improvement in erectile function over time [177].

7.2.6 **Quality of life after partial penectomy**

Several qualitative and quantitative instruments were used to assess 'psychological behaviour and adjustment' and 'social activity' as QoL indicators [176]. Patients reported fears of mutilation and of loss of sexual pleasure, as well as fear of dying and what this would mean for their families. Patients said family and partners were important in overcoming difficulties following surgery. The study reported no significant levels of anxiety and depression on the GHQ-12 (General Health Questionnaire) and HAD scale (Hospital Anxiety and Depression Scale), 'Social activity' remained the same after surgery in terms of living conditions, family life and social interactions.

7.3 **Total phallic reconstruction**

There is very limited data about total phallic reconstruction [118, 178, 179] following full- or near-total penile amputation. It is not possible to restore function. Cosmetically acceptable results are obtainable.

7.4 **Specialised care**

It is possible to cure almost 80% of penile cancer patients at all stages. Whenever possible, organ-preserving treatment should be offered [48] as it permits better QoL and sexual function than with partial penectomy. Patients should be referred to an experienced centre. Psychological support is very important for penile cancer patients.

8. REFERENCES

1. Hakenberg, O.W., *et al.* EAU guidelines on penile cancer: 2014 update. *Eur Urol*, 2015. 67: 142. <http://www.ncbi.nlm.nih.gov/pubmed/25457021>
2. Clark, P.E., *et al.* Penile cancer: Clinical Practice Guidelines in Oncology. *J Natl Compr Canc Netw*, 2013. 11: 594. <http://www.ncbi.nlm.nih.gov/pubmed/23667209>
3. Souillac, I., *et al.* [Penile cancer in 2010: update from the Oncology Committee of the French Association of Urology: external genital organs group (CCAFU-OGE)]. *Prog Urol*, 2011. 21: 909. <http://www.ncbi.nlm.nih.gov/pubmed/22118355>
4. Van Poppel, H., *et al.* Penile cancer: ESMO Clinical Practice Guidelines for diagnosis, treatment and follow-up. *Ann Oncol*, 2013. 24 Suppl 6: vi115. <http://www.ncbi.nlm.nih.gov/pubmed/23975666>
5. Phillips B, *et al.* Oxford Centre for Evidence-based Medicine Levels of Evidence. Updated by Jeremy Howick March 2009. 1998. <http://www.cebm.net/oxford-centre-evidence-based-medicine-levels-evidence-march-2009/>
6. Backes, D.M., *et al.* Systematic review of human papillomavirus prevalence in invasive penile cancer. *Cancer Causes Control*, 2009. 20: 449. <http://www.ncbi.nlm.nih.gov/pubmed/19082746>
7. Chaux, A., *et al.* Epidemiologic profile, sexual history, pathologic features, and human papillomavirus status of 103 patients with penile carcinoma. *World J Urol*, 2013. 31: 861. <http://www.ncbi.nlm.nih.gov/pubmed/22116602>

8. Cancer Incidence in Five Continents Vol. VIII. IARC Scientific Publication No. 155. Vol. Vol III. 2002, The International Agency for Research on Cancer, 150 cours Albert Thomas, 69372 Lyon CEDEX 08, France.
<http://www.iarc.fr/en/publications/pdfs-online/epi/sp155/>
9. Parkin, D.M., *et al.* Chapter 2: The burden of HPV-related cancers. *Vaccine*, 2006. 24 Suppl 3: S3/11.
<http://www.ncbi.nlm.nih.gov/pubmed/16949997>
10. Baldur-Felskov, B., *et al.* Increased incidence of penile cancer and high-grade penile intraepithelial neoplasia in Denmark 1978-2008: a nationwide population-based study. *Cancer Causes Control*, 2012. 23: 273.
<http://www.ncbi.nlm.nih.gov/pubmed/22101453>
11. Arya, M., *et al.* Long-term trends in incidence, survival and mortality of primary penile cancer in England. *Cancer Causes Control*, 2013. 24: 2169.
<http://www.ncbi.nlm.nih.gov/pubmed/24101363>
12. Barnholtz-Sloan, J.S., *et al.* Incidence trends in primary malignant penile cancer. *Urol Oncol*, 2007. 25: 361.
<http://www.ncbi.nlm.nih.gov/pubmed/17826651>
13. Dillner, J., *et al.* Etiology of squamous cell carcinoma of the penis. *Scand J Urol Nephrol Suppl*, 2000: 189.
<http://www.ncbi.nlm.nih.gov/pubmed/11144896>
14. Maden, C., *et al.* History of circumcision, medical conditions, and sexual activity and risk of penile cancer. *J Natl Cancer Inst*, 1993. 85: 19.
<http://www.ncbi.nlm.nih.gov/pubmed/8380060>
15. Tsen, H.F., *et al.* Risk factors for penile cancer: results of a population-based case-control study in Los Angeles County (United States). *Cancer Causes Control*, 2001. 12: 267.
<http://www.ncbi.nlm.nih.gov/pubmed/11405332>
16. Archier, E., *et al.* Carcinogenic risks of psoralen UV-A therapy and narrowband UV-B therapy in chronic plaque psoriasis: a systematic literature review. *J Eur Acad Dermatol Venereol*, 2012. 26 Suppl 3: 22.
<http://www.ncbi.nlm.nih.gov/pubmed/22512677>
17. Stern, R.S. The risk of squamous cell and basal cell cancer associated with psoralen and ultraviolet A therapy: a 30-year prospective study. *J Am Acad Dermatol*, 2012. 66: 553.
<http://www.ncbi.nlm.nih.gov/pubmed/22264671>
18. Daling, J.R., *et al.* Cigarette smoking and the risk of anogenital cancer. *Am J Epidemiol*, 1992. 135: 180.
<http://www.ncbi.nlm.nih.gov/pubmed/1311142>
19. Stankiewicz, E., *et al.* HPV infection and immunochemical detection of cell-cycle markers in verrucous carcinoma of the penis. *Mod Pathol*, 2009. 22: 1160.
<http://www.ncbi.nlm.nih.gov/pubmed/19465901>
20. Koifman, L., *et al.* Epidemiological aspects of penile cancer in Rio de Janeiro: evaluation of 230 cases. *Int Braz J Urol*, 2011. 37: 231.
<http://www.ncbi.nlm.nih.gov/pubmed/21557840>
21. Thuret, R., *et al.* A population-based analysis of the effect of marital status on overall and cancer-specific mortality in patients with squamous cell carcinoma of the penis. *Cancer Causes Control*, 2013. 24: 71.
<http://www.ncbi.nlm.nih.gov/pubmed/23109172>
22. McIntyre, M., *et al.* Penile cancer: an analysis of socioeconomic factors at a southeastern tertiary referral center. *Can J Urol*, 2011. 18: 5524.
<http://www.ncbi.nlm.nih.gov/pubmed/21333043>
23. Benard, V.B., *et al.* Examining the association between socioeconomic status and potential human papillomavirus-associated cancers. *Cancer*, 2008. 113: 2910.
<http://www.ncbi.nlm.nih.gov/pubmed/18980274>
24. Ulf-Moller, C.J., *et al.* Marriage, cohabitation and incidence trends of invasive penile squamous cell carcinoma in Denmark 1978-2010. *Int J Cancer*, 2013. 133: 1173.
<http://www.ncbi.nlm.nih.gov/pubmed/23404289>
25. Kayes, O., *et al.* Molecular and genetic pathways in penile cancer. *Lancet Oncol*, 2007. 8: 420.
<http://www.ncbi.nlm.nih.gov/pubmed/17466899>
26. Munoz, N., *et al.* Chapter 1: HPV in the etiology of human cancer. *Vaccine*, 2006. 24 Suppl 3: S3/1.
<http://www.ncbi.nlm.nih.gov/pubmed/16949995>

27. Nordenvall, C., *et al.* Cancer risk among patients with condylomata acuminata. *Int J Cancer*, 2006. 119: 888.
<http://www.ncbi.nlm.nih.gov/pubmed/16557590>
28. Lont, A.P., *et al.* Presence of high-risk human papillomavirus DNA in penile carcinoma predicts favorable outcome in survival. *Int J Cancer*, 2006. 119: 1078.
<http://www.ncbi.nlm.nih.gov/pubmed/16570278>
29. Bezerra, A.L., *et al.* Human papillomavirus as a prognostic factor in carcinoma of the penis: analysis of 82 patients treated with amputation and bilateral lymphadenectomy. *Cancer*, 2001. 91: 2315.
<http://www.ncbi.nlm.nih.gov/pubmed/11413520>
30. Philippou, P., *et al.* Genital lichen sclerosus/balanitis xerotica obliterans in men with penile carcinoma: a critical analysis. *BJU Int*, 2013. 111: 970.
<http://www.ncbi.nlm.nih.gov/pubmed/23356463>
31. D'Hauwers, K.W., *et al.* Human papillomavirus, lichen sclerosus and penile cancer: a study in Belgium. *Vaccine*, 2012. 30: 6573.
<http://www.ncbi.nlm.nih.gov/pubmed/22939906>
32. Newman, P.A., *et al.* HPV vaccine acceptability among men: a systematic review and meta-analysis. *Sex Transm Infect*, 2013. 89: 568.
<http://www.ncbi.nlm.nih.gov/pubmed/23828943>
33. Fisher, H., *et al.* Inequalities in the uptake of human papillomavirus vaccination: a systematic review and meta-analysis. *Int J Epidemiol*, 2013. 42: 896.
<http://www.ncbi.nlm.nih.gov/pubmed/23620381>
34. Van Howe, R.S., *et al.* The carcinogenicity of smegma: debunking a myth. *J Eur Acad Dermatol Venereol*, 2006. 20: 1046.
<http://www.ncbi.nlm.nih.gov/pubmed/16987256>
35. Daling, J.R., *et al.* Penile cancer: importance of circumcision, human papillomavirus and smoking in in situ and invasive disease. *Int J Cancer*, 2005. 116: 606.
<http://www.ncbi.nlm.nih.gov/pubmed/15825185>
36. Velazquez, E.F., *et al.* Limitations in the interpretation of biopsies in patients with penile squamous cell carcinoma. *Int J Surg Pathol*, 2004. 12: 139.
<http://www.ncbi.nlm.nih.gov/pubmed/15173919>
37. Velazquez, E.F., *et al.* Lichen sclerosus in 68 patients with squamous cell carcinoma of the penis: frequent atypias and correlation with special carcinoma variants suggests a precancerous role. *Am J Surg Pathol*, 2003. 27: 1448.
<http://www.ncbi.nlm.nih.gov/pubmed/14576478>
38. Teichman, J.M., *et al.* Noninfectious penile lesions. *Am Fam Physician*, 2010. 81: 167.
<http://www.ncbi.nlm.nih.gov/pubmed/20082512>
39. Renaud-Vilmer, C., *et al.* Analysis of alterations adjacent to invasive squamous cell carcinoma of the penis and their relationship with associated carcinoma. *J Am Acad Dermatol*, 2010. 62: 284.
<http://www.ncbi.nlm.nih.gov/pubmed/20115951>
40. Cubilla, A.L., *et al.* Pathologic features of epidermoid carcinoma of the penis. A prospective study of 66 cases. *Am J Surg Pathol*, 1993. 17: 753.
<http://www.ncbi.nlm.nih.gov/pubmed/8338190>
41. Chauv, A., *et al.* Papillary squamous cell carcinoma, not otherwise specified (NOS) of the penis: clinicopathologic features, differential diagnosis, and outcome of 35 cases. *Am J Surg Pathol*, 2010. 34: 223.
<http://www.ncbi.nlm.nih.gov/pubmed/20061934>
42. Mannweiler, S., *et al.* Clear-cell differentiation and lymphatic invasion, but not the revised TNM classification, predict lymph node metastases in pT1 penile cancer: a clinicopathologic study of 76 patients from a low incidence area. *Urol Oncol*, 2013. 31: 1378.
<http://www.ncbi.nlm.nih.gov/pubmed/22421354>
43. Gunia, S., *et al.* Inherent grading characteristics of individual pathologists contribute to clinically and prognostically relevant interobserver discordance concerning Broders' grading of penile squamous cell carcinomas. *Urol Int*, 2013. 90: 207.
<http://www.ncbi.nlm.nih.gov/pubmed/23108244>
44. Oertell, J., *et al.* Differentiated precursor lesions and low-grade variants of squamous cell carcinomas are frequent findings in foreskins of patients from a region of high penile cancer incidence. *Histopathology*, 2011. 58: 925.
<http://www.ncbi.nlm.nih.gov/pubmed/21585428>

45. Cubilla, A.L. The role of pathologic prognostic factors in squamous cell carcinoma of the penis. *World J Urol*, 2009. 27: 169.
<http://www.ncbi.nlm.nih.gov/pubmed/18766352>
46. Velazquez, E.F., *et al.* Epithelial abnormalities and precancerous lesions of anterior urethra in patients with penile carcinoma: a report of 89 cases. *Mod Pathol*, 2005. 18: 917.
<http://www.ncbi.nlm.nih.gov/pubmed/15920559>
47. Rees, R.W., *et al.* pT2 penile squamous cell carcinomas: cavernosus vs. spongiosus invasion. *Eur Urol Suppl*, 2008. 7: 111.
[http://www.europeanurology.com/article/S1569-9056\(08\)60162-1/fulltext](http://www.europeanurology.com/article/S1569-9056(08)60162-1/fulltext)
48. Leijte, J.A., *et al.* Evaluation of current TNM classification of penile carcinoma. *J Urol*, 2008. 180: 933.
<http://www.ncbi.nlm.nih.gov/pubmed/18635216>
49. Solsona, E., *et al.* Prospective validation of the association of local tumor stage and grade as a predictive factor for occult lymph node micrometastasis in patients with penile carcinoma and clinically negative inguinal lymph nodes. *J Urol*, 2001. 165: 1506.
<http://www.ncbi.nlm.nih.gov/pubmed/11342906>
50. Hungerhuber, E., *et al.* Risk stratification in penile carcinoma: 25-year experience with surgical inguinal lymph node staging. *Urology*, 2006. 68: 621.
<http://www.ncbi.nlm.nih.gov/pubmed/16979733>
51. Chau, A., *et al.* The prognostic index: a useful pathologic guide for prediction of nodal metastases and survival in penile squamous cell carcinoma. *Am J Surg Pathol*, 2009. 33: 1049.
<http://www.ncbi.nlm.nih.gov/pubmed/19384188>
52. Fromont, G., *et al.* 8q24 amplification is associated with Myc expression and prostate cancer progression and is an independent predictor of recurrence after radical prostatectomy. *Hum Pathol*, 2013. 44: 1617.
<http://www.ncbi.nlm.nih.gov/pubmed/23574779>
53. Alves, G., *et al.* Genetic imbalances in 26 cases of penile squamous cell carcinoma. *Genes Chromosomes Cancer*, 2001. 31: 48.
<http://www.ncbi.nlm.nih.gov/pubmed/11284035>
54. Alves, G., *et al.* Determination of telomerase activity in squamous cell carcinoma of the penis. *Int J Oncol*, 2001. 18: 67.
<http://www.ncbi.nlm.nih.gov/pubmed/11115540>
55. Kayes, O.J., *et al.* DNA replication licensing factors and aneuploidy are linked to tumor cell cycle state and clinical outcome in penile carcinoma. *Clin Cancer Res*, 2009. 15: 7335.
<http://www.ncbi.nlm.nih.gov/pubmed/19920109>
56. Gunia, S., *et al.* p16(INK4a) is a marker of good prognosis for primary invasive penile squamous cell carcinoma: a multi-institutional study. *J Urol*, 2012. 187: 899.
<http://www.ncbi.nlm.nih.gov/pubmed/22245329>
57. Poetsch, M., *et al.* Alterations in the tumor suppressor gene p16(INK4A) are associated with aggressive behavior of penile carcinomas. *Virchows Arch*, 2011. 458: 221.
<http://www.ncbi.nlm.nih.gov/pubmed/21085986>
58. Gunia, S., *et al.* Expression of p53, p21 and cyclin D1 in penile cancer: p53 predicts poor prognosis. *J Clin Pathol*, 2012. 65: 232.
<http://www.ncbi.nlm.nih.gov/pubmed/22135025>
59. Protzel, C., *et al.* Down-regulation of the metastasis suppressor protein KAI1/CD82 correlates with occurrence of metastasis, prognosis and presence of HPV DNA in human penile squamous cell carcinoma. *Virchows Arch*, 2008. 452: 369.
<http://www.ncbi.nlm.nih.gov/pubmed/18305955>
60. Velazquez, E.F., *et al.* Positive resection margins in partial penectomies: sites of involvement and proposal of local routes of spread of penile squamous cell carcinoma. *Am J Surg Pathol*, 2004. 28: 384.
<http://www.ncbi.nlm.nih.gov/pubmed/15104302>
61. Minhas, S., *et al.* What surgical resection margins are required to achieve oncological control in men with primary penile cancer? *BJU Int*, 2005. 96: 1040.
<http://www.ncbi.nlm.nih.gov/pubmed/16225525>
62. Sarma, A.V., *et al.* Risk factors for urinary incontinence among women with type 1 diabetes: findings from the epidemiology of diabetes interventions and complications study. *Urology*, 2009. 73: 1203.
<http://www.ncbi.nlm.nih.gov/pubmed/19362350>

63. Bertolotto, M., *et al.* Primary and secondary malignancies of the penis: ultrasound features. *Abdom Imaging*, 2005. 30: 108.
<http://www.ncbi.nlm.nih.gov/pubmed/15759326>
64. Lont, A.P., *et al.* A comparison of physical examination and imaging in determining the extent of primary penile carcinoma. *BJU Int*, 2003. 91: 493.
<http://www.ncbi.nlm.nih.gov/pubmed/12656901>
65. Kayes, O., *et al.* The role of magnetic resonance imaging in the local staging of penile cancer. *Eur Urol*, 2007. 51: 1313.
<http://www.ncbi.nlm.nih.gov/pubmed/17113213>
66. Petralia, G., *et al.* Local staging of penile cancer using magnetic resonance imaging with pharmacologically induced penile erection. *Radiol Med*, 2008. 113: 517.
<http://www.ncbi.nlm.nih.gov/pubmed/18478188>
67. Krishna, R.P., *et al.* Sonography: an underutilized diagnostic tool in the assessment of metastatic groin nodes. *J Clin Ultrasound*, 2008. 36: 212.
<http://www.ncbi.nlm.nih.gov/pubmed/17960822>
68. Mueller-Lisse, U.G., *et al.* Functional imaging in penile cancer: PET/computed tomography, MRI, and sentinel lymph node biopsy. *Curr Opin Urol*, 2008. 18: 105.
<http://www.ncbi.nlm.nih.gov/pubmed/18090498>
69. Leijte, J.A., *et al.* Prospective evaluation of hybrid 18F-fluorodeoxyglucose positron emission tomography/computed tomography in staging clinically node-negative patients with penile carcinoma. *BJU Int*, 2009. 104: 640.
<http://www.ncbi.nlm.nih.gov/pubmed/19281465>
70. Schlenker, B., *et al.* Detection of inguinal lymph node involvement in penile squamous cell carcinoma by 18F-fluorodeoxyglucose PET/CT: a prospective single-center study. *Urol Oncol*, 2012. 30: 55.
<http://www.ncbi.nlm.nih.gov/pubmed/20022269>
71. Alkatout, I., *et al.* Squamous cell carcinoma of the penis: predicting nodal metastases by histologic grade, pattern of invasion and clinical examination. *Urol Oncol*, 2011. 29: 774.
<http://www.ncbi.nlm.nih.gov/pubmed/20060332>
72. Graafland, N.M., *et al.* Prognostic factors for occult inguinal lymph node involvement in penile carcinoma and assessment of the high-risk EAU subgroup: a two-institution analysis of 342 clinically node-negative patients. *Eur Urol*, 2010. 58: 742.
<http://www.ncbi.nlm.nih.gov/pubmed/20800339>
73. Souillac, I., *et al.* Prospective evaluation of (18)F-fluorodeoxyglucose positron emission tomography-computerized tomography to assess inguinal lymph node status in invasive squamous cell carcinoma of the penis. *J Urol*, 2012. 187: 493.
<http://www.ncbi.nlm.nih.gov/pubmed/22177157>
74. Horenblas, S., *et al.* Squamous cell carcinoma of the penis. III. Treatment of regional lymph nodes. *J Urol*, 1993. 149: 492.
<http://www.ncbi.nlm.nih.gov/pubmed/8437253>
75. Ornellas, A.A., *et al.* Surgical treatment of invasive squamous cell carcinoma of the penis: retrospective analysis of 350 cases. *J Urol*, 1994. 151: 1244.
<http://www.ncbi.nlm.nih.gov/pubmed/7512656>
76. Zhu, Y., *et al.* Predicting pelvic lymph node metastases in penile cancer patients: a comparison of computed tomography, Cloquet's node, and disease burden of inguinal lymph nodes. *Onkologie*, 2008. 31: 37.
<http://www.ncbi.nlm.nih.gov/pubmed/18268397>
77. Graafland, N.M., *et al.* Scanning with 18F-FDG-PET/CT for detection of pelvic nodal involvement in inguinal node-positive penile carcinoma. *Eur Urol*, 2009. 56: 339.
<http://www.ncbi.nlm.nih.gov/pubmed/19477581>
78. Zhu, Y., *et al.* The value of squamous cell carcinoma antigen in the prognostic evaluation, treatment monitoring and followup of patients with penile cancer. *J Urol*, 2008. 180: 2019.
<http://www.ncbi.nlm.nih.gov/pubmed/18801542>
79. Leijte, J.A., *et al.* Recurrence patterns of squamous cell carcinoma of the penis: recommendations for follow-up based on a two-centre analysis of 700 patients. *Eur Urol*, 2008. 54: 161.
<http://www.ncbi.nlm.nih.gov/pubmed/18440124>
80. Alnajjar, H.M., *et al.* Treatment of carcinoma in situ of the glans penis with topical chemotherapy agents. *Eur Urol*, 2012. 62: 923.
<http://www.ncbi.nlm.nih.gov/pubmed/22421082>

81. Paoli, J., *et al.* Penile intraepithelial neoplasia: results of photodynamic therapy. *Acta Derm Venereol*, 2006. 86: 418.
<http://www.ncbi.nlm.nih.gov/pubmed/16955186>
82. Shabbir, M., *et al.* Glans resurfacing for the treatment of carcinoma in situ of the penis: surgical technique and outcomes. *Eur Urol*, 2011. 59: 142.
<http://www.ncbi.nlm.nih.gov/pubmed/21050658>
83. Philippou, P., *et al.* Conservative surgery for squamous cell carcinoma of the penis: resection margins and long-term oncological control. *J Urol*, 2012. 188: 803.
<http://www.ncbi.nlm.nih.gov/pubmed/22818137>
84. Ornellas, A.A., *et al.* Surgical treatment of invasive squamous cell carcinoma of the penis: Brazilian National Cancer Institute long-term experience. *J Surg Oncol*, 2008. 97: 487.
<http://www.ncbi.nlm.nih.gov/pubmed/18425779>
85. Bandieramonte, G., *et al.* Peniscopically controlled CO2 laser excision for conservative treatment of in situ and T1 penile carcinoma: report on 224 patients. *Eur Urol*, 2008. 54: 875.
<http://www.ncbi.nlm.nih.gov/pubmed/18243513>
86. Colecchia, M., *et al.* pT1 penile squamous cell carcinoma: a clinicopathologic study of 56 cases treated by CO2 laser therapy. *Anal Quant Cytol Histol*, 2009. 31: 153.
<http://www.ncbi.nlm.nih.gov/pubmed/19639702>
87. Piva, L., *et al.* [Therapeutic alternatives in the treatment of class T1N0 squamous cell carcinoma of the penis: indications and limitations]. *Arch Ital Urol Androl*, 1996. 68: 157.
<http://www.ncbi.nlm.nih.gov/pubmed/8767503>
88. Frimberger, D., *et al.* Penile carcinoma. Is Nd:YAG laser therapy radical enough? *J Urol*, 2002. 168: 2418.
<http://www.ncbi.nlm.nih.gov/pubmed/12441930>
89. Meijer, R.P., *et al.* Long-term follow-up after laser therapy for penile carcinoma. *Urology*, 2007. 69: 759.
<http://www.ncbi.nlm.nih.gov/pubmed/17445665>
90. Rothenberger, K.H., *et al.* [Laser therapy of penile carcinoma]. *Urologe A*, 1994. 33: 291.
<http://www.ncbi.nlm.nih.gov/pubmed/7941174>
91. Schlenker, B., *et al.* Organ-preserving neodymium-yttrium-aluminium-garnet laser therapy for penile carcinoma: a long-term follow-up. *BJU Int*, 2010. 106: 786.
<http://www.ncbi.nlm.nih.gov/pubmed/20089106>
92. Schlenker, B., *et al.* Intermediate-differentiated invasive (pT1 G2) penile cancer--oncological outcome and follow-up. *Urol Oncol*, 2011. 29: 782.
<http://www.ncbi.nlm.nih.gov/pubmed/19945307>
93. Skeppner, E., *et al.* Treatment-seeking, aspects of sexual activity and life satisfaction in men with laser-treated penile carcinoma. *Eur Urol*, 2008. 54: 631.
<http://www.ncbi.nlm.nih.gov/pubmed/18788122>
94. Windahl, T., *et al.* Combined laser treatment for penile carcinoma: results after long-term followup. *J Urol*, 2003. 169: 2118.
<http://www.ncbi.nlm.nih.gov/pubmed/12771731>
95. Tietjen, D.N., *et al.* Laser therapy of squamous cell dysplasia and carcinoma of the penis. *Urology*, 1998. 52: 559.
<http://www.ncbi.nlm.nih.gov/pubmed/9763071>
96. van Bezooijen, B.P., *et al.* Laser therapy for carcinoma in situ of the penis. *J Urol*, 2001. 166: 1670.
<http://www.ncbi.nlm.nih.gov/pubmed/11586199>
97. Mohs, F.E., *et al.* Mohs micrographic surgery for penile tumors. *Urol Clin North Am*, 1992. 19: 291.
<http://www.ncbi.nlm.nih.gov/pubmed/1574820>
98. Shindel, A.W., *et al.* Mohs micrographic surgery for penile cancer: management and long-term followup. *J Urol*, 2007. 178: 1980.
<http://www.ncbi.nlm.nih.gov/pubmed/17869306>
99. Hadway, P., *et al.* Total glans resurfacing for premalignant lesions of the penis: initial outcome data. *BJU Int*, 2006. 98: 532.
<http://www.ncbi.nlm.nih.gov/pubmed/16925748>
100. Ayres, B., *et al.*, Glans resurfacing – a new penile preserving option for superficially invasive penile cancer. 2010.
101. Austoni E, G.A., *et al.*, Reconstructive surgery for penile cancer with preservation of sexual function. *Eur Urol Suppl*, 2008. 7: 116 (Abstract #183).

102. Li, J., *et al.* Organ-sparing surgery for penile cancer: complications and outcomes. *Urology*, 2011. 78: 1121.
<http://www.ncbi.nlm.nih.gov/pubmed/22054385>
103. Smith, Y., *et al.* Reconstructive surgery for invasive squamous carcinoma of the glans penis. *Eur Urol*, 2007. 52: 1179.
<http://www.ncbi.nlm.nih.gov/pubmed/17349734>
104. Morelli, G., *et al.* Glansectomy with split-thickness skin graft for the treatment of penile carcinoma. *Int J Impot Res*, 2009. 21: 311.
<http://www.ncbi.nlm.nih.gov/pubmed/19458620>
105. Khezri, A.A., *et al.* Carcinoma of the penis. *Br J Urol*, 1978. 50: 275.
<http://www.ncbi.nlm.nih.gov/pubmed/753475>
106. Modig, H., *et al.* Carcinoma of the penis. Treatment by surgery or combined bleomycin and radiation therapy. *Acta Oncol*, 1993. 32: 653.
<http://www.ncbi.nlm.nih.gov/pubmed/7505090>
107. Persky, L., *et al.* Carcinoma of the penis. *CA Cancer J Clin*, 1986. 36: 258.
<http://www.ncbi.nlm.nih.gov/pubmed/3093013>
108. Lummen, G., *et al.* [Treatment and follow-up of patients with squamous epithelial carcinoma of the penis]. *Urologe A*, 1997. 36: 157.
<http://www.ncbi.nlm.nih.gov/pubmed/9199044>
109. Crook, J., *et al.*, MP-21.03: Penile brachytherapy: results for 60 patients. *Urology*, 2007. 70: 161.
110. Crook, J., *et al.* Penile brachytherapy: technical aspects and postimplant issues. *Brachytherapy*, 2010. 9: 151.
<http://www.ncbi.nlm.nih.gov/pubmed/19854685>
111. Crook, J., *et al.* Radiation therapy in the management of the primary penile tumor: an update. *World J Urol*, 2009. 27: 189.
<http://www.ncbi.nlm.nih.gov/pubmed/18636264>
112. de Crevoisier, R., *et al.* Long-term results of brachytherapy for carcinoma of the penis confined to the glans (N- or NX). *Int J Radiat Oncol Biol Phys*, 2009. 74: 1150.
<http://www.ncbi.nlm.nih.gov/pubmed/19395183>
113. Gotsadze, D., *et al.* Is conservative organ-sparing treatment of penile carcinoma justified? *Eur Urol*, 2000. 38: 306.
<http://www.ncbi.nlm.nih.gov/pubmed/10940705>
114. Ozsahin, M., *et al.* Treatment of penile carcinoma: to cut or not to cut? *Int J Radiat Oncol Biol Phys*, 2006. 66: 674.
<http://www.ncbi.nlm.nih.gov/pubmed/16949770>
115. Crook, J.M., *et al.* American Brachytherapy Society-Groupe Europeen de Curietherapie-European Society of Therapeutic Radiation Oncology (ABS-GEC-ESTRO) consensus statement for penile brachytherapy. *Brachytherapy*, 2013. 12: 191.
<http://www.ncbi.nlm.nih.gov/pubmed/23453681>
116. Azrif, M., *et al.* External-beam radiotherapy in T1-2 N0 penile carcinoma. *Clin Oncol (R Coll Radiol)*, 2006. 18: 320.
<http://www.ncbi.nlm.nih.gov/pubmed/16703750>
117. Zouhair, A., *et al.* Radiation therapy alone or combined surgery and radiation therapy in squamous-cell carcinoma of the penis? *Eur J Cancer*, 2001. 37: 198.
<http://www.ncbi.nlm.nih.gov/pubmed/11166146>
118. Garaffa, G., *et al.* Total phallic reconstruction after penile amputation for carcinoma. *BJU Int*, 2009. 104: 852.
<http://www.ncbi.nlm.nih.gov/pubmed/19239449>
119. Salgado, C.J., *et al.* Glans penis coronoplasty with palmaris longus tendon following total penile reconstruction. *Ann Plast Surg*, 2009. 62: 690.
<http://www.ncbi.nlm.nih.gov/pubmed/19461287>
120. Saisorn, I., *et al.* Fine-needle aspiration cytology predicts inguinal lymph node metastasis without antibiotic pretreatment in penile carcinoma. *BJU Int*, 2006. 97: 1225.
<http://www.ncbi.nlm.nih.gov/pubmed/16686716>
121. Rosevear, H.M., *et al.* Utility of (1)(8)F-FDG PET/CT in identifying penile squamous cell carcinoma metastatic lymph nodes. *Urol Oncol*, 2012. 30: 723.
<http://www.ncbi.nlm.nih.gov/pubmed/21396850>
122. Horenblas, S. Lymphadenectomy for squamous cell carcinoma of the penis. Part 1: diagnosis of lymph node metastasis. *BJU Int*, 2001. 88: 467.
<http://www.ncbi.nlm.nih.gov/pubmed/11589659>

123. Stuijver, M.M., *et al.* Early wound complications after inguinal lymphadenectomy in penile cancer: a historical cohort study and risk-factor analysis. *Eur Urol*, 2013. 64: 486.
<http://www.ncbi.nlm.nih.gov/pubmed/23490726>
124. Koifman, L., *et al.* Radical open inguinal lymphadenectomy for penile carcinoma: surgical technique, early complications and late outcomes. *J Urol*, 2013. 190: 2086.
<http://www.ncbi.nlm.nih.gov/pubmed/23770135>
125. Yao, K., *et al.* Modified technique of radical inguinal lymphadenectomy for penile carcinoma: morbidity and outcome. *J Urol*, 2010. 184: 546.
<http://www.ncbi.nlm.nih.gov/pubmed/20620415>
126. Hegarty, P.K., *et al.* Controversies in ilioinguinal lymphadenectomy. *Urol Clin North Am*, 2010. 37: 421.
<http://www.ncbi.nlm.nih.gov/pubmed/20674697>
127. Lughezzani, G., *et al.* The Relationship Between Lymph Node Ratio and Cancer-Specific Survival in a Contemporary Series of Patients with Penile Cancer and Lymph Node Metastases. *BJU Int*, 2013. 116: 727.
<http://www.ncbi.nlm.nih.gov/pubmed/24128128>
128. Protzel, C., *et al.* Lymphadenectomy in the surgical management of penile cancer. *Eur Urol*, 2009. 55: 1075.
<http://www.ncbi.nlm.nih.gov/pubmed/19264390>
129. Thuret, R., *et al.* A contemporary population-based assessment of the rate of lymph node dissection for penile carcinoma. *Ann Surg Oncol*, 2011. 18: 439.
<http://www.ncbi.nlm.nih.gov/pubmed/20839061>
130. La-Touche, S., *et al.* Trial of ligation vs. coagulation of lymphatics in dynamic inguinal sentinel lymph node biopsy for staging of squamous cell carcinoma of the penis. *Ann R Coll Surg Engl*, 2012. 94: 344.
<http://www.ncbi.nlm.nih.gov/pubmed/22943231>
131. Tauber, R., *et al.* Inguinal lymph node dissection: epidermal vacuum therapy for prevention of wound complications. *J Plast Reconstr Aesthet Surg*, 2013. 66: 390.
<http://www.ncbi.nlm.nih.gov/pubmed/23107617>
132. Pahwa, H.S., *et al.* Video Endoscopic Inguinal Lymphadenectomy (VEIL)--a prospective critical perioperative assessment of feasibility and morbidity with points of technique in penile carcinoma. *World J Surg Oncol*, 2013. 11: 42.
<http://www.ncbi.nlm.nih.gov/pubmed/23432959>
133. Zhou, X.L., *et al.* Endoscopic inguinal lymphadenectomy for penile carcinoma and genital malignancy: a preliminary report. *J Endourol*, 2013. 27: 657.
<http://www.ncbi.nlm.nih.gov/pubmed/23268699>
134. Matin, S.F., *et al.* Phase 1 prospective evaluation of the oncological adequacy of robotic assisted video-endoscopic inguinal lymphadenectomy in patients with penile carcinoma. *BJU Int*, 2013. 111: 1068.
<http://www.ncbi.nlm.nih.gov/pubmed/23551693>
135. Tobias-Machado, M., *et al.* Video endoscopic inguinal lymphadenectomy: a new minimally invasive procedure for radical management of inguinal nodes in patients with penile squamous cell carcinoma. *J Urol*, 2007. 177: 953.
<http://www.ncbi.nlm.nih.gov/pubmed/17296386>
136. Cabanas, R.M. An approach for the treatment of penile carcinoma. *Cancer*, 1977. 39: 456.
<http://www.ncbi.nlm.nih.gov/pubmed/837331>
137. Lughezzani, G., *et al.* The relationship between characteristics of inguinal lymph nodes and pelvic lymph node involvement in penile squamous cell carcinoma: a single institution experience. *J Urol*, 2014. 191: 977.
<http://www.ncbi.nlm.nih.gov/pubmed/24262497>
138. Graafland, N.M., *et al.* Prognostic significance of extranodal extension in patients with pathological node positive penile carcinoma. *J Urol*, 2010. 184: 1347.
<http://www.ncbi.nlm.nih.gov/pubmed/20723934>
139. Lucky, M.A., *et al.* Referrals into a dedicated British penile cancer centre and sources of possible delay. *Sex Transm Infect*, 2009. 85: 527.
<http://www.ncbi.nlm.nih.gov/pubmed/19584061>
140. Pizzocaro, G., *et al.* Adjuvant and neoadjuvant vincristine, bleomycin, and methotrexate for inguinal metastases from squamous cell carcinoma of the penis. *Acta Oncol*, 1988. 27: 823.
<http://www.ncbi.nlm.nih.gov/pubmed/2466471>

141. Leijte, J.A., *et al.* Neoadjuvant chemotherapy in advanced penile carcinoma. *Eur Urol*, 2007. 52: 488.
<http://www.ncbi.nlm.nih.gov/pubmed/17316964>
142. Bermejo, C., *et al.* Neoadjuvant chemotherapy followed by aggressive surgical consolidation for metastatic penile squamous cell carcinoma. *J Urol*, 2007. 177: 1335.
<http://www.ncbi.nlm.nih.gov/pubmed/17382727>
143. Pizzocaro, G., *et al.* Taxanes in combination with cisplatin and fluorouracil for advanced penile cancer: preliminary results. *Eur Urol*, 2009. 55: 546.
<http://www.ncbi.nlm.nih.gov/pubmed/18649992>
144. Graafland, N.M., *et al.* Inguinal recurrence following therapeutic lymphadenectomy for node positive penile carcinoma: outcome and implications for management. *J Urol*, 2011. 185: 888.
<http://www.ncbi.nlm.nih.gov/pubmed/21239009>
145. Kulkarni, J.N., *et al.* Prophylactic bilateral groin node dissection vs. prophylactic radiotherapy and surveillance in patients with N0 and N1-2A carcinoma of the penis. *Eur Urol*, 1994. 26: 123.
<http://www.ncbi.nlm.nih.gov/pubmed/7957466>
146. Franks, K.N., *et al.* Radiotherapy for node positive penile cancer: experience of the Leeds teaching hospitals. *J Urol*, 2011. 186: 524.
<http://www.ncbi.nlm.nih.gov/pubmed/21700296>
147. Burt, L.M., *et al.* Stage presentation, care patterns, and treatment outcomes for squamous cell carcinoma of the penis. *Int J Radiat Oncol Biol Phys*, 2014. 88: 94.
<http://www.ncbi.nlm.nih.gov/pubmed/24119832>
148. Sonpavde, G., *et al.* Penile cancer: current therapy and future directions. *Ann Oncol*, 2013. 24: 1179.
<http://www.ncbi.nlm.nih.gov/pubmed/23293117>
149. Maiche, A.G. Adjuvant treatment using bleomycin in squamous cell carcinoma of penis: study of 19 cases. *Br J Urol*, 1983. 55: 542.
<http://www.ncbi.nlm.nih.gov/pubmed/6194844>
150. Pizzocaro, G., *et al.* Up-to-date management of carcinoma of the penis. *Eur Urol*, 1997. 32: 5.
<http://www.ncbi.nlm.nih.gov/pubmed/9266225>
151. Giannatempo P., *et al.* Survival analyses of adjuvant or neoadjuvant combination of a taxane plus cisplatin and 5-fluorouracil (T-PF) in patients with bulky nodal metastases from squamous cell carcinoma of the penis (PSCC): Results of a single high-volume center. *J Clin Oncol*, 2014. 32: 5.
<http://meetinglibrary.asco.org/content/124205-142>
152. Noronha, V., *et al.* Role of paclitaxel and platinum-based adjuvant chemotherapy in high-risk penile cancer. *Urol Ann*, 2012. 4: 150.
<http://www.ncbi.nlm.nih.gov/pubmed/23248520>
153. Hakenberg, O.W., *et al.* Cisplatin, methotrexate and bleomycin for treating advanced penile carcinoma. *BJU Int*, 2006. 98: 1225.
<http://www.ncbi.nlm.nih.gov/pubmed/17125480>
154. Haas, G.P., *et al.* Cisplatin, methotrexate and bleomycin for the treatment of carcinoma of the penis: a Southwest Oncology Group study. *J Urol*, 1999. 161: 1823.
<http://www.ncbi.nlm.nih.gov/pubmed/10332445>
155. Hussein, A.M., *et al.* Chemotherapy with cisplatin and 5-fluorouracil for penile and urethral squamous cell carcinomas. *Cancer*, 1990. 65: 433.
<http://www.ncbi.nlm.nih.gov/pubmed/2297633>
156. Shammas, F.V., *et al.* Cisplatin and 5-fluorouracil in advanced cancer of the penis. *J Urol*, 1992. 147: 630.
<http://www.ncbi.nlm.nih.gov/pubmed/1538445>
157. Theodore, C., *et al.* A phase II multicentre study of irinotecan (CPT 11) in combination with cisplatin (CDDP) in metastatic or locally advanced penile carcinoma (EORTC PROTOCOL 30992). *Ann Oncol*, 2008. 19: 1304.
<http://www.ncbi.nlm.nih.gov/pubmed/18417462>
158. Pagliaro, L.C., *et al.* Neoadjuvant paclitaxel, ifosfamide, and cisplatin chemotherapy for metastatic penile cancer: a phase II study. *J Clin Oncol*, 2010. 28: 3851.
<http://www.ncbi.nlm.nih.gov/pubmed/20625118>
159. Nicholson, S., *et al.* Phase II trial of docetaxel, cisplatin and 5FU chemotherapy in locally advanced and metastatic penis cancer (CRUK/09/001). *Br J Cancer*, 2013. 109: 2554.
<http://www.ncbi.nlm.nih.gov/pubmed/24169355>
160. Eliason, M., *et al.* Primary treatment of verrucous carcinoma of the penis with fluorouracil, cis-diamino-dichloro-platinum, and radiation therapy. *Arch Dermatol*, 2009. 145: 950.
<http://www.ncbi.nlm.nih.gov/pubmed/19687438>

161. Pond, G.R., *et al.* Prognostic risk stratification derived from individual patient level data for men with advanced penile squamous cell carcinoma receiving first-line systemic therapy. *Urol Oncol*, 2014. 32: 501.
<http://www.ncbi.nlm.nih.gov/pubmed/24332646>
162. Di Lorenzo, G., *et al.* Cisplatin and 5-fluorouracil in inoperable, stage IV squamous cell carcinoma of the penis. *BJU Int*, 2012. 110: E661.
<http://www.ncbi.nlm.nih.gov/pubmed/22958571>
163. Di Lorenzo, G., *et al.* Paclitaxel in pretreated metastatic penile cancer: final results of a phase 2 study. *Eur Urol*, 2011. 60: 1280.
<http://www.ncbi.nlm.nih.gov/pubmed/21871710>
164. Power, D.G., *et al.* Cisplatin and gemcitabine in the management of metastatic penile cancer. *Urol Oncol*, 2009. 27: 187.
<http://www.ncbi.nlm.nih.gov/pubmed/18367122>
165. Gou, H.F., *et al.* Epidermal growth factor receptor (EGFR)-RAS signaling pathway in penile squamous cell carcinoma. *PLoS One*, 2013. 8: e62175.
<http://www.ncbi.nlm.nih.gov/pubmed/23637996>
166. Necchi, A., *et al.* Proof of activity of anti-epidermal growth factor receptor-targeted therapy for relapsed squamous cell carcinoma of the penis. *J Clin Oncol*, 2011. 29: e650.
<http://www.ncbi.nlm.nih.gov/pubmed/21632506>
167. Carthon, B.C., *et al.* Epidermal growth factor receptor-targeted therapy in locally advanced or metastatic squamous cell carcinoma of the penis. *BJU Int*, 2014. 113: 871.
<http://www.ncbi.nlm.nih.gov/pubmed/24053151>
168. Zhu, Y., *et al.* Feasibility and activity of sorafenib and sunitinib in advanced penile cancer: a preliminary report. *Urol Int*, 2010. 85: 334.
<http://www.ncbi.nlm.nih.gov/pubmed/20980789>
169. Kroon, B.K., *et al.* Patients with penile carcinoma benefit from immediate resection of clinically occult lymph node metastases. *J Urol*, 2005. 173: 816.
<http://www.ncbi.nlm.nih.gov/pubmed/15711276>
170. Horenblas, S., *et al.* Local recurrent tumour after penis-conserving therapy. A plea for long-term follow-up. *Br J Urol*, 1993. 72: 976.
<http://www.ncbi.nlm.nih.gov/pubmed/8306171>
171. Djajadiningrat, R.S., *et al.* Penile Sparing Surgery for Penile Cancer-Does it Affect Survival? *J Urol*, 2013.
<http://www.ncbi.nlm.nih.gov/pubmed/24373799>
172. Kroon, B.K., *et al.* Ultrasonography-guided fine-needle aspiration cytology before sentinel node biopsy in patients with penile carcinoma. *BJU Int*, 2005. 95: 517.
<http://www.ncbi.nlm.nih.gov/pubmed/15705071>
173. Djajadiningrat, R.S., *et al.* Ultrasound examination and fine needle aspiration cytology-useful for followup of the regional nodes in penile cancer? *J Urol*, 2014. 191: 652.
<http://www.ncbi.nlm.nih.gov/pubmed/23994372>
174. Schover, L.R. Sexuality and fertility after cancer. *Hematology Am Soc Hematol Educ Program*, 2005: 523.
<http://www.ncbi.nlm.nih.gov/pubmed/16304430>
175. Romero, F.R., *et al.* Sexual function after partial penectomy for penile cancer. *Urology*, 2005. 66: 1292.
<http://www.ncbi.nlm.nih.gov/pubmed/16360459>
176. D'Ancona, C.A., *et al.* Quality of life after partial penectomy for penile carcinoma. *Urology*, 1997. 50: 593.
<http://www.ncbi.nlm.nih.gov/pubmed/9338738>
177. Alei, G., *et al.* Lichen sclerosus in patients with squamous cell carcinoma. Our experience with partial penectomy and reconstruction with ventral fenestrated flap. *Ann Ital Chir*, 2012. 83: 363.
<http://www.ncbi.nlm.nih.gov/pubmed/22759475>
178. Gerullis, H., *et al.* Construction of a penoid after penectomy using a transpositioned testicle. *Urol Int*, 2013. 90: 240.
<http://www.ncbi.nlm.nih.gov/pubmed/22922734>
179. Hage, J.J. Simple, safe, and satisfactory secondary penile enhancement after near-total oncologic amputation. *Ann Plast Surg*, 2009. 62: 685.
<http://www.ncbi.nlm.nih.gov/pubmed/19461286>

9. CONFLICT OF INTEREST

All members of the Penile Cancer Guidelines working group have provided disclosure statements of all relationships that they have that might be perceived as a potential source of a conflict of interest. This information is publicly accessible through the European Association of Urology website: <http://www.uroweb.org/guidelines/>. This guidelines document was developed with the financial support of the European Association of Urology. No external sources of funding and support have been involved. The EAU is a non-profit organisation and funding is limited to administrative assistance and travel and meeting expenses. No honoraria or other reimbursements have been provided.

